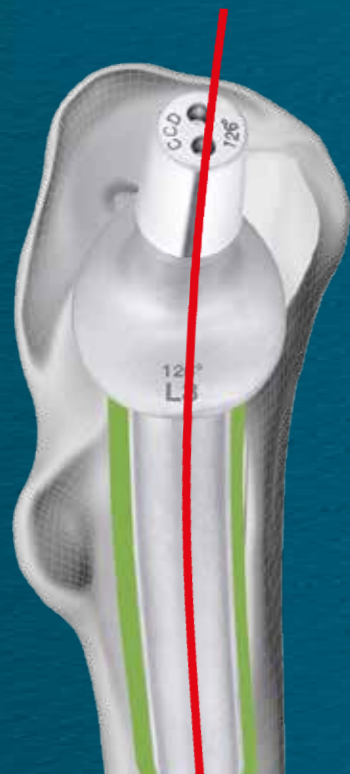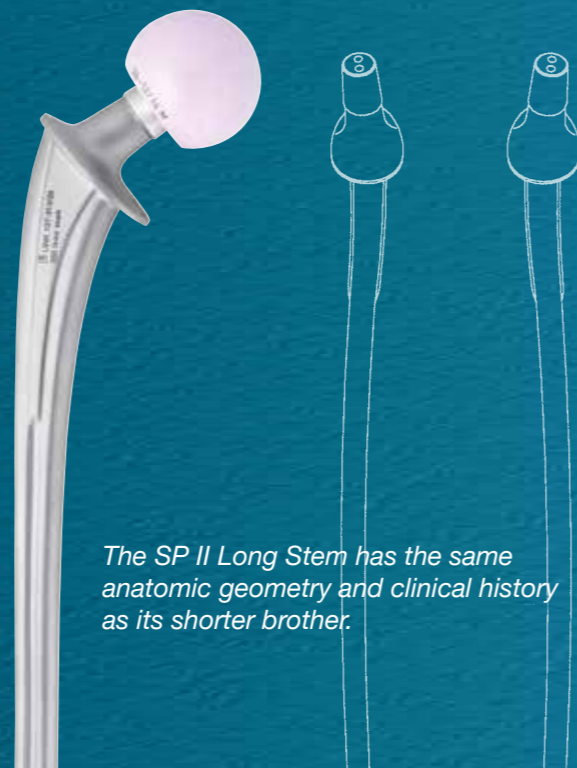


Anatomic Shape

Shape aligns with anatomy of femur ⁵

- Physiological transmission of forces ^{2, 3, 4}
- Strong **neutralisation** of torsion forces ^{2, 3, 4}
- Built in anteversion matches native anatomy ⁵



The SP II Long Stem has the same anatomic geometry and clinical history as its shorter brother.

LINK Lubinus SP II Long Stem & Revision

1. Kärrholm, Lindahl, Malchau, Mohaddes, Rogmark, Rolison, ANNUAL REPORT 2015; The Swedish Hip Arthroplasty Register
2. Langhans, M., Hofman, D., Eke, H., & Nietert, M. (1992). Der Einfluß der Formgebung des Prothesenschaftes auf die Beanspruchung des proximalen Femurs. Unfallchirurgie, 18 (6), pp. 266-273.
3. Noble, P., Alexander, J., Lindahl, L., Yew, D., Granberry, W., & Tullos, H. (1988). The anatomic basis of femoral component design. Clinical Orthopaedics and Related Research(235), pp. 148-165.
4. W.T. Stillwell. The Art of the Total Arthroplasty. Grune & Stratton, Inc. 1987, pp. 296
5. Internal Document
6. S. Sesselmann, Y. Hong, F. Schlemmer, K. Wiendieck, S. Söder, I. Hussenaetter, L. A. Müller, R. Forst, T. Wierer. Migration measurement of the cemented Lubinus SP II hip stem – a 10-year follow-up using radiostereometric analysis, Biomed. Eng. -Biomed. Tech. 2017; 62 (3): 271-276
7. Waldemar Link GmbH & Co. KG · Helmut D. Link, 25 Jahre SP II- Eine Erfolgsgeschichte, direktLINK Magazin für Endoprothetik Sonderausgabe / Oktober 2009, p. 6
8. Garellick, Kärrholm, Rogmark, Rolison, Herberts, ANNUAL REPORT 2014; The Swedish National Hip Arthroplasty Register.; p. 75
9. Malchau H, Herberts P, Ahnfeldt L. Prognosis of total hip replacement in Sweden. Follow-up of 92.675 operations performed 1978-1990. Acta Orthop Scand 1993; 64 (5): 497-506
10. Wierer T, Forst R, Mueller LA, Sesselmann S. Biomed Tech (Berl.) 2013 Aug; 58 (4): 333-41. DOI: 10.1515/bmt-2012-0038. Radiostereometric migration analysis of the Lubinus SP II hip stem: 59 hips followed for 2 years
11. High risk of early periprosthetic fracture after primary hip arthroplasty in elderly patients using a cemented, tapered, polished stem: An observational, prospective cohort study on 1,403 hips with 47 fractures after a mean follow-up time of 4 years-åBroden C, Mukka S, Muren O, Eisler Stark A, Skoldenberg O, Acta Orthopaedica 2015; 86 (1)

LINK • 6433_SP II_Teaserflyer_EN_2021-08_004_MAR_01252_4.0

Waldemar Link GmbH & Co. KG
Barkhausenweg 10 · 22339 Hamburg · Germany
Phone +49 40 53995-0 · info@linkhh.de
www.linkorthopaedics.com

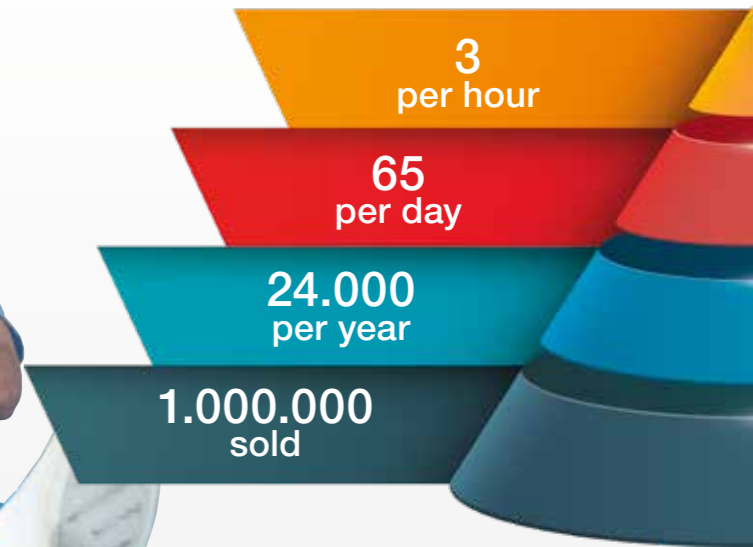


LINK Lubinus SP II 40 Years of Experience

Successful for more than 40 Years ¹

Satisfying Patients & Surgeons ^{6, 7}

Proven through profound Clinical Data ^{1, 8}



15A* ODEP rating

www.odep.org.uk; Orthopaedic Data Evaluation Panel

1978

Successful

Satisfying

Proven



Over 40 years of success ¹

- One of the most used cemented hip stems worldwide ⁶
- Extensive clinical follow-up ¹
- Low demand surgical technique ⁹

The anatomic design causes satisfaction ^{6,7}

- Low incidence of peri-prosthetic fractures ¹¹
- Improved HHS after surgery ^{4,6}
- Minimised risk of aseptic loosening ¹⁰

Proven through profound clinical data

- Outstanding longterm results ^{1,8}
- Unchanged for decades ⁵
- 92.3% survivorship after 23 years ^{1,8}