

Pelvic Ring Injuries - An overview

Ian Pallister

The management of pelvic ring injuries is in a state of great flux. As a junior in Trauma and Orthopaedics I listened intently to stories of the emergency application of external fixators as part of the management of the exsanguinating patient in the Resusc. Room. Just as the management of the patient in *extremis* has changed beyond recognition, so the focus of interest in pelvic ring injuries has broadened enormously.



Ian Pallister is a civilian orthopaedic trauma surgeon whose clinical and research interests include the management of and recovery from major trauma including pelvic ring injuries and open fractures. He also has a major commitment to simulation in training for time-critical emergencies and is co-director of the Damage Control in Orthopaedic Trauma Surgery (DCOTS) Course.

Multicentre studies in the UK aim to arm us with evidence on which to base decisions (with patients) about which injuries may or may not benefit from surgery. In particular low energy transfer insufficiency fractures and 'new technologies' are receiving structured evaluation in a manner never seen before. Foremost in our considerations are of course the patients, and the life they will lead after the injury has healed. Major gaps in our knowledge exist in truly determining the quality of life of our patients – gaps which will only be filled by recognising them and engaging with patients to determine how to record, measure and improve future outcomes.

The Exsanguinating Patient with a Pelvic Ring Injury

Damage control resuscitation underpins the approach to managing exsanguinating trauma patients including those with pelvic ring injuries. The UK Defence Medical Services achieved unparalleled improvements in probability of survival for casualties in the recent Afghan conflict but applying a series of technique from the point-of-wounding to definitive care with the simple goals of minimising blood loss and restoring tissue perfusion¹. The signature injury pattern of the conflict was massive blast trauma caused by improvised

explosive devices², the pelvic element of which is described in the following article by Rankin et al.

The establishment of major trauma networks has provided fertile ground for these philosophies to take root in the civilian setting. The liberal use of pelvic binders in the pre-hospital phase is a welcome development as the sooner the pelvic volume is reduced, with accompanying increase in intra-pelvic pressure³, the sooner venous bleeding may be brought under control (Figure 1 and 2). Military experience shows that clot stabilisation using tranexamic acid may be more effective in the most severely injured than indicated by the Crash 2 study⁴. The widespread use of massive haemorrhage protocols brings us closer to replacing lost blood appropriately, rather than making an attempt to stabilise an acidotic borderline coagulopathic patient using 'balanced' electrolyte solutions (which are themselves acidic) or synthetic starches (which interfere with clotting).

Should these strategies fail to improve the patient's condition and bleeding from the pelvic injury continues, further immediate action is required. Trauma CT scanning protocols include an angiographic phase which can be immensely helpful in identifying active arterial bleeding. The argument over whether to proceed to pelvic packing or interventional radiology for angio-embolisation misses the central point⁵. >>

The patient who is bleeding to death requires immediate intervention⁶. Extra-peritoneal pelvic packing is a systematic but simple technique which can be completed very rapidly. It is important to pack against the stability provided by a pelvic binder. If direct control of major vessels is required, this can be accomplished through the same exposure and the expertise of a vascular surgeon can be invaluable. Once in a position to allow the trauma anaesthetist to increase transfusion, perfusion and lastly blood pressure, consideration should be given to stabilising the pelvic ring injury either with a simple iliac crest external fixator or with a symphyseal plate. It may have proven necessary to do all of this before going to CT, in which case, once hypovolaemic shock is clearly being controlled, CT scan should be the next destination *en route* to ITU. Angio-embolisation can be very effective

but survival rates have been shown to be comparable in units which do not have the capability to deliver this technique⁷. A selective approach to the use of these techniques is logical and likely to be the most effective.

“Damage control resuscitation underpins the approach to managing exsanguinating trauma patients including those with pelvic ring injuries. The UK Defence Medical Services achieved unparalleled improvements in probability of survival for casualties in the recent Afghan conflict but applying a series of technique from the point-of-wounding to definitive care with the simple goals of minimising blood loss and restoring tissue perfusion.”

The subject of definitive stabilisation of pelvic ring injuries is a specialised area beyond the scope of this paper. A much more common question that faces us is “when is it safe to remove the pelvic

binder?” The answer can be found in an understanding of the purpose of the pelvic binder. Binders serve only to reduce pelvic displacement, increase intra-pelvic pressure and thus tamponade venous bleeding in injuries which have increased

the pelvic volume. If the patient has not been in hypovolaemic shock, the binder can be safely removed. As a source of pain-relief skin traction is more comfortable and appears more effective, while it also helps stabilise the injured hemipelvis. A loose pelvic binder serves no purpose at all. The

removal of a binder in a patient whose hypovolaemic shock has resolved should ideally be discussed with a local pelvic trauma surgeon. Once stable clot has formed, provided the patient is not moved carelessly, secondary haemorrhage is inherently unlikely. Catastrophic complications from continued binder use are rare but can and do occur⁸.

Pelvic ring injuries associated with hypovolaemic shock and potentially delayed mobilisation have been shown to be at particular risk of thrombo-embolic problems⁹. Further evidence from combat casualties indicates that thrombo-embolic complications can occur very early after injury in those rescued from profound hypovolaemic shock¹⁰. The ideal regimen for thromboprophylaxis remains to be determined, but the potential use of caval filters should be borne in mind.

New Perspectives – How Can We Determine Which Injuries Benefit from Surgery?

As confidence in the range of operative techniques to stabilise pelvic injuries increases, so the indications for these to be used seems to broaden. The role of operative stabilisation in lateral compression fractures and

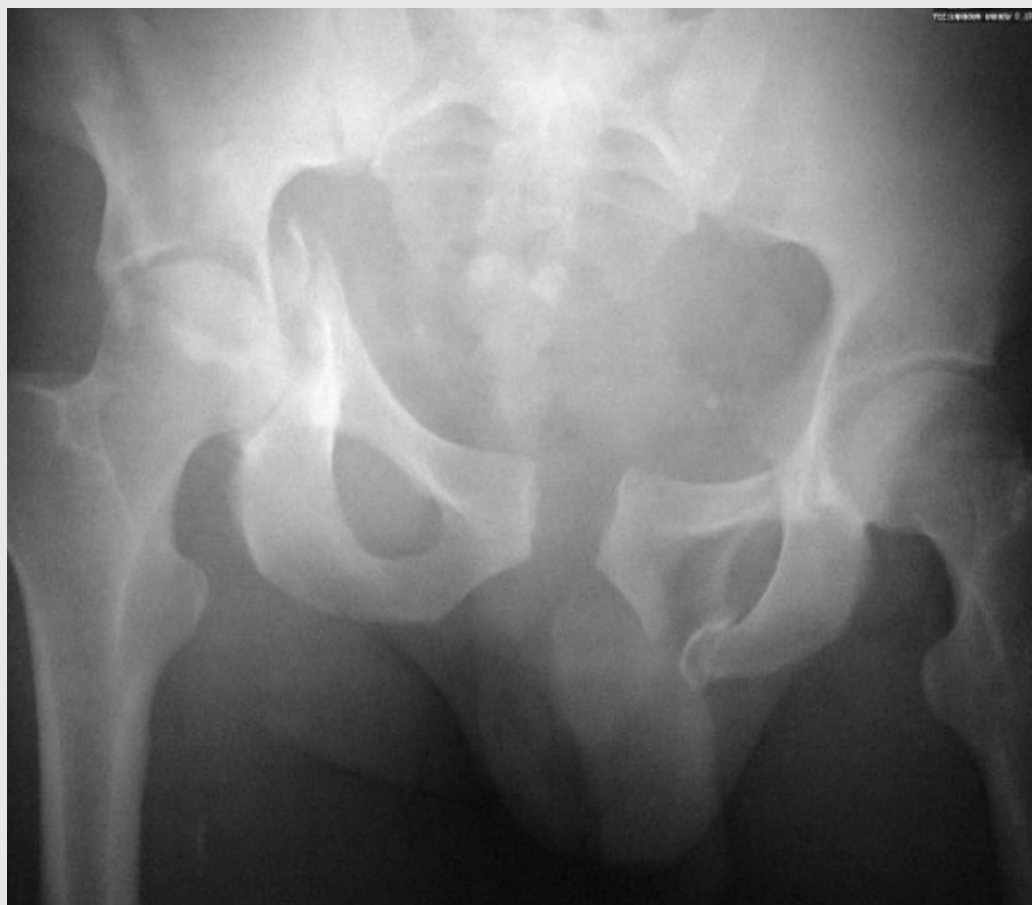

Figure 1: Correct application of a pelvic binder can achieve excellent reduction and increase intra-pelvic pressure, helping to control potentially catastrophic venous bleeding.

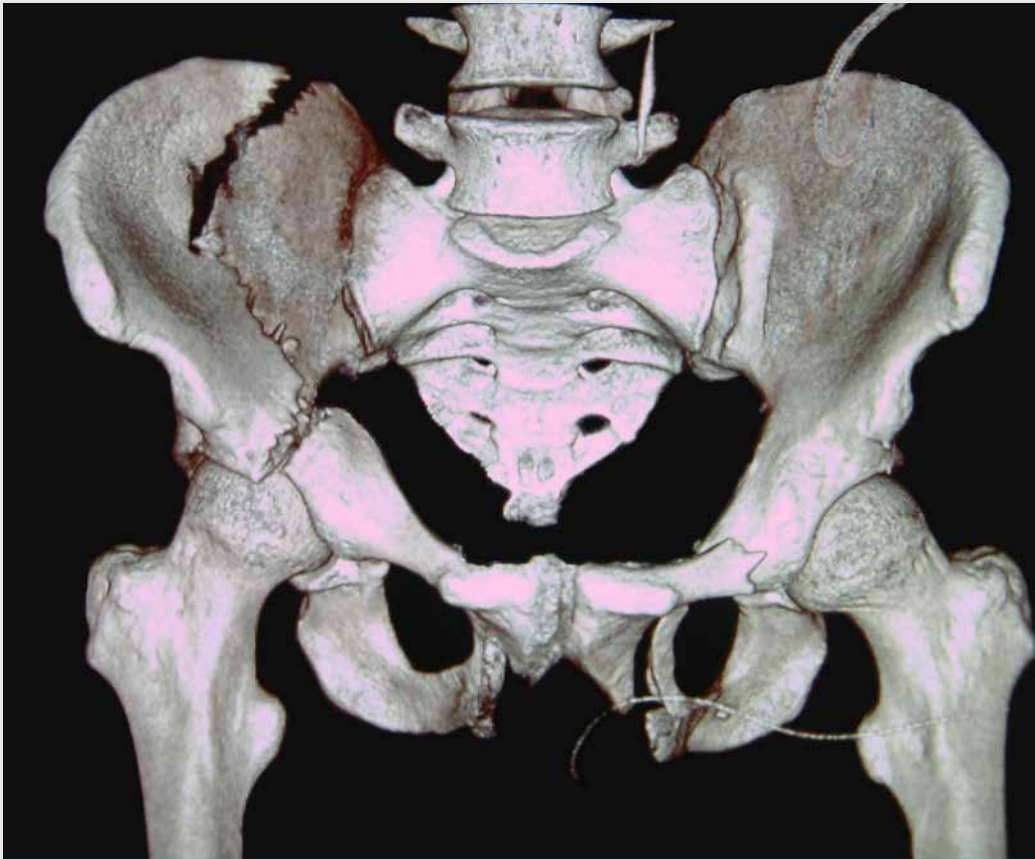


Figure 2: Correct application of a pelvic binder can achieve excellent reduction and increase intra-pelvic pressure, helping to control potentially catastrophic venous bleeding.

in insufficiency fractures in particular has always been an area of greater uncertainty than in other injury patterns. The adoption and adaptation of spinal instrumentation in place of supra-acetabular external fixation has heralded the development of INFIX techniques¹¹. Although the insertion of the supra-acetabular pin and tunnelled bar is minimally invasive, it is not without potential acute complications including major vessel occlusion, and metalwork removal can often be required¹².

Fragility fractures seem to be ever more common despite effective treatments to address bone health¹³.

While the surgical management of proximal femoral fractures is accepted as a crucial element in the care of such patients, the role of pelvic fracture stabilisation is yet to be fully determined.

Major multi-centre randomised studies are under way in the UK at present. The LiFE study compares anterior internal surgical fixation (i.e. INFIX) with non-

surgical management in lateral compression type 1 injuries in patients over the age of 60 (ISRCTN16478561). The primary outcome is health related quality of life (EQ-5D-5L) over the 12 months after injury. This study aims to recruit 600 patients over its course.

Another is the Trial of sUrgical vs non-surgical treatment of Lateral compression Injuries of the Pelvis (TULIP) compares these treatment approaches in the non-fragility age group¹³ (ISRCTN10649958). As a feasibility study, the primary aim is to determine recruitment rates and enable the completion of a produce a CONSORT (consolidated

“Fragility fractures seem to be ever more common despite effective treatments to address bone health. While the surgical management of proximal femoral fractures is accepted as a crucial element in the care of such patients, the role of pelvic fracture stabilisation is yet to be fully determined.”

standards of reporting trials) diagram reporting screening, recruitment, randomisation, compliance and include allocation proportions by centre. While generic health-related quality of life measures are undoubtedly useful in large-scale studies, the development of more injury specific metric has been proposed¹⁴. The development of such tools can be a lengthy process. Many questions remain unanswered in the recovery after pelvic trauma, and the more detailed the questions posed, the more intrusive and unwelcome they may be. However, in the following paper by Bott et al. the under-reported urological and sexual difficulties that post pelvic ring injury patients encounter are outlined.

The clinic environment in which pelvic fracture patients are reviewed by the orthopaedic trauma team is usually deeply unsuitable to ask questions about sexual function and continence. The public nature of the consultation spaces lends itself only to discussion along standard fracture clinic lines. It can be argued that

these problems do not fall into the area of responsibility of orthopaedic trauma specialists. Direct physical injury to the uro-genital tract is mercifully relatively rare, but the findings of the following study clearly show that a great many patients have related problems which go unreported and so unaddressed.

While the ideal means of describing the nature of these problems for research purposes and also quantifying their severity for research purposes is yet to be determined, the clinical imperative to recognise these problems and direct patients to appropriate help remains.

The results of current multi-centre studies and the future development of new injury specific patient centred outcomes will help us refine our management of the whole spectrum of pelvic ring injuries, enabling us to combine logical evolutions in surgical practice with strong scientifically based clinical evidence. ■

References

References can be found online at www.boa.ac.uk/publications/JTO.