

Srinath Ranjit¹, Dhruvin Sangoi¹, Nicholas Cullen¹, Shelain Patel¹, Matthew Welck² & Karan Malhotra²

¹ Foot & Ankle Unit, Royal National Orthopaedic Hospital, Stanmore, United Kingdom,

² Department of Ortho & MSK Science, UCL, Foot & Ankle Unit, Royal National Orthopaedic Hospital, Stanmore, United Kingdom

Introduction

Weightbearing-CT (WB-CT) is increasingly used in analysis of complex foot deformities however commonly used measurements are based on 2D slices and do not accurately assess coronal plane deformity. 3D-segmentation is a novel method of determining foot morphology and the relationships of bones in multiple planes. This study assesses the coronal plane deformities in cavovarus feet secondary to Charcot-Marie Tooth disease (CMT) using WB-CT and automated 3D-segmentation software.

Methods and Materials

WB-CTs from 30 CMT cavovarus feet were matched to 30 controls and analysed using automatic 3D-segmentation (Bonelogic, DISIOR). The coronal relationship within each joint and the pronation/supination of individual bones in relation to the floor was analyzed. Statistical analysis was performed using independent samples t-tests.

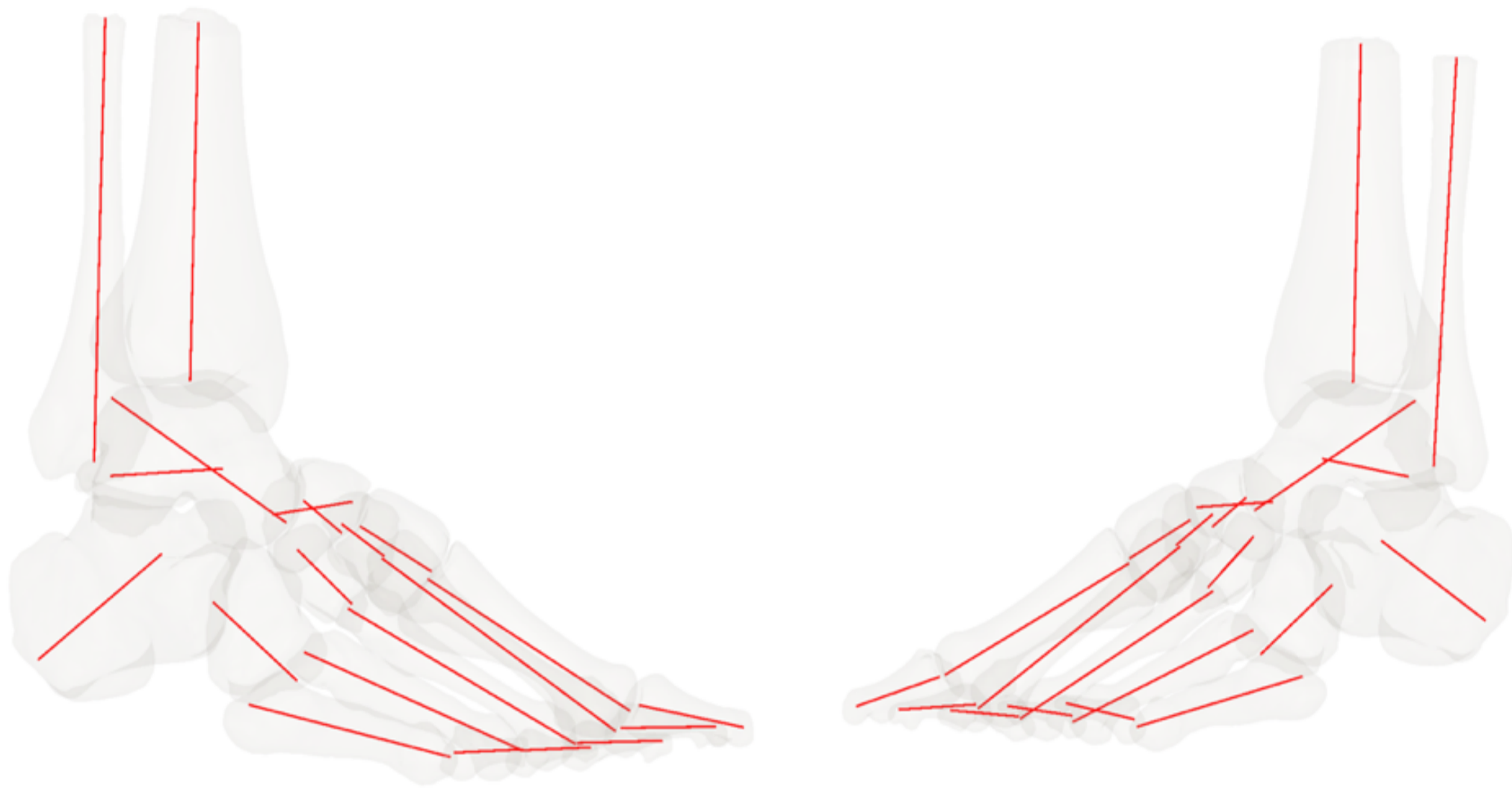


Fig 1: Illustrated is the virtual 3D model generated by the software of a cavovarus foot. Each bone is segmented and the individual axes for each bone are modelled.

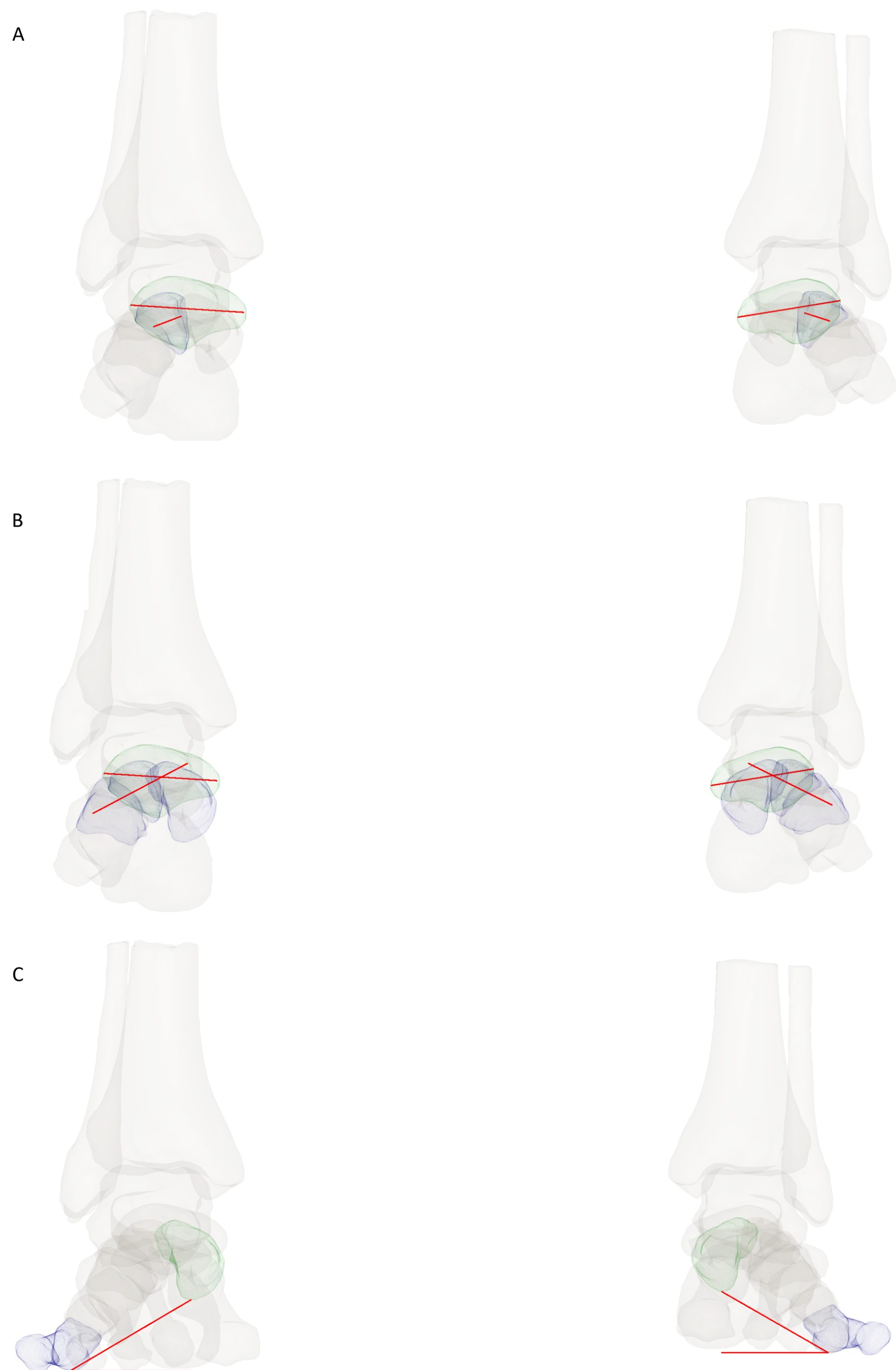


Figure 2: Illustrated are some of the coronal measurements calculated. Figure 2A: Coronal Navicular-Intermediate Cuneiform angle. Figure 2B: Coronal Navicular-Mean Cuneiform angle. Figure 2C: Forefoot arch angle.

Measurements (Coronal Plane)	Mean (\pm Standard Deviation)		Mean Difference	p
	Normal	Cavus		
Hindfoot				
Tibio-Talar Tilt Angle (deg) ‡	-0.1 (\pm 0.9)	3.7 (\pm 18.9)	3.8	0.276
Talar-Calcaneal Angle (deg) †	24.1 (\pm 9.9)	16.0 (\pm 26.5)	-8.1	0.123
Hindfoot Moment Arm (mm) †	3.3 (\pm 5.3)	-10.4 (\pm 10.0)	-13.7	0.000*
Saltzman 45 Degree View (deg) ‡	4.4 (\pm 5.4)	25.0 (\pm 13.0)	20.6	0.000*
Midfoot				
Talo-Navicular Rotation Angle (deg) †	29.4 (\pm 7.0)	6.4 (\pm 14.5)	-23.0	0.000*
Navicular-1st Cuneiform Angle (deg) †	-37.8 (\pm 5.5)	-26.9 (\pm 9.8)	10.9	0.000*
Navicular-2nd Cuneiform Angle (deg) †	-34.0 (\pm 6.8)	-28.5 (\pm 9.7)	5.4	0.015*
Navicular-3rd Cuneiform Angle (deg) †	-59.1 (\pm 6.0)	-54.4 (\pm 6.4)	4.7	0.005*
Navicular-Cuneiform Mean Angle (deg) †	-43.0 (\pm 5.3)	-36.0 (\pm 6.6)	7.0	0.000*

Table 1 - Coronal plane Hindfoot and midfoot measurements of individual bones. Significant results denoted with an *. Where measured variable denoted with †, +ve difference = pronation / valgus, -ve difference = supination / varus. Where measured variable denoted with ‡, +ve difference = supination / varus, -ve difference = pronation / valgus.

Measurement (Coronal Plane)	Mean (\pm Standard Deviation)		Mean Difference	p
	Normal	Cavus		
Hindfoot				
Talar-Floor Angle (deg)	2.6 (\pm 3.4)	6.4 (\pm 11.5)	3.8	0.090
Midfoot				
Navicular-Floor Angle (deg)	-26.8 (\pm 7.0)	0.0 (\pm 13.6)	26.8	0.000*
1 st Cuneiform-Ground Angle (deg)	11.0 (\pm 7.1)	26.9 (\pm 13.1)	15.9	0.000*
2 nd Cuneiform-Ground Angle (deg)	7.2 (\pm 8.1)	28.5 (\pm 14.5)	21.4	0.000*
3 rd Cuneiform-Ground Angle (deg)	32.3 (\pm 7.1)	54.4 (\pm 12.5)	22.1	0.000*
Cuneiform Mean-Ground Angle (deg)	16.2 (\pm 6.8)	36.0 (\pm 12.1)	19.8	0.000*
Forefoot				
Forefoot Arch Angle (deg)	16.0 (\pm 4.8)	36.9 (\pm 19.8)	20.9	0.000*
Proximal 1 st Metatarsal-Ground Angle (deg)	-0.1 (\pm 8.0)	19.4 (\pm 11.8)	19.5	0.000*

Table 2 - Specific Coronal plane Hindfoot, midfoot and forefoot measurements of individual bones in respect to horizontal axis in Cavus vs Normal cohort. Significant results denoted with an *. For all values, a +ve difference in means = supination and a -ve difference = pronation.

Results

The most significant deformity in CMT cavovarus occurred at the Talonavicular joint (TNJ) which had 23 degrees more supination than normal feet. This was countered by pronation at the naviculo-cuneiform joints (NCJ), particularly the medial cuneiform-navicular joint, where there was relative pronation of 10.9 degrees compared to normal feet. Combined hindfoot varus and supination at the TNJ results in an additive supination effect which was not fully compensated by pronation at the NCJ. The cuneiforms and first metatarsal were therefore relatively supinated with respect to the ground compared to normal feet (19.8 degrees). The forefoot arch and first metatarsal ground angle demonstrated similar supination to the cuneiforms suggesting no further rotation at the tarsometatarsal joints.

Conclusions

This study quantifies the complex coronal plane deformities present in CMT cavus feet which need consideration during management of these patients. Our results demonstrate that after untwisting the TNJ and correcting the hindfoot, coronal deformity may persist and majority of this occurs at the NCJ. Future work in this area may help in accurate assessment and surgical planning in the management of complex cavus foot deformities.