

ZIMMER BOA TRAVELLING FELLOWSHIP AWARD 2019

SUMMARY 250 WORDS (245)

This invaluable travelling fellowship included visits to two prestigious upper limb centres in North America in November.

Firstly, I visited the world-famous Steadman Clinic in Vail, Colorado, where I spent time with leading surgeon, Dr Peter Millett. Both himself and his colleagues have operated on and successfully treated leading world athletes from a variety of sports and activities. Millett designed the widely-used Speedbridge 'double-row' repair for rotator cuff tears and has been integral in the advancement of superior capsular reconstruction (SCR) for irreparable cuff tears. He also created the minimally-invasive Complete Arthroscopic Management (CAM) procedure for advanced OA in active patients who wish to post-pone arthroplasty.

I then spent time with the highly-respected Prof George Athwal in the Roth McFarlane Hand & Upper Limb Centre in London, Ontario. The centre was established in 1992 by its two founders and has gone on to become Canada's leading upper limb centre. Following his time working in France and collaborative work with European upper limb surgeons, Athwal has gone on to be recognised internationally for his expertise in shoulder arthroplasty and instability.

I gained a great deal from both Dr Millett and Prof Athwal (Figure 1). In addition, I had the opportunity to spend time in clinic and theatre with their orthopaedic colleagues, also world leaders in their fields. The experience as a whole was both unique and priceless with regards to the tips and techniques learnt that will no doubt contribute to both my ability as an upper limb surgeon.

REPORT 1000 WORDS (Educational and clinical benefits)

DR PETER MILLETT, STEADMAN CLINIC
(VAIL, COLORADO, USA):

On entering the Steadman Clinic, you're welcomed by a statue of founder Richard Steadman. Inside, the walls are graced by signed sports jerseys and memorabilia from numerous high-level performers, from footballers to astronauts. All 16 surgeons have teams of fellows and highly-skilled physician's assistants (PA) and clinic rooms with certificates, awards and gifts plastered indulgently over the walls, highlighting each 'attending' surgeon's success.

The private clinic thrives on efficiency, both in clinic and the operating room (OR). While the case mix is similar to the UK, the patient cohort is more active, wealthy and international, coming in to be treated by the 'best surgeon(s) in the world'. The majority of new patients, having failed non-operative management, generally had an expectation of surgery. In theatre, two ORs ran simultaneously but staggered. The PA and fellow would start and the attending would do the main procedure before

moving next-door as the PA closed. The first thing I noticed was that there was no lamina flow in any of the theatres but infection rates were still apparently very low.

While I was able to observe a variety of cases performed, one of the reasons to visit Dr Millett was due to his excellent outcomes with rotator cuff repairs, which he presented in England two years ago. He published the original work on the Speedbridge technique approximately 15 years ago so the experience he has with arthroscopic cuff repairs is second to none. Cuff repairs were reproduced with military precision, effectively debriding and releasing the torn tendon, preparing the footprint with microfracture and meticulously undertaking the double-row repair (Figure 2). Routine 6-week follow-up US scans confirmed solid repairs in all the cases I saw. In addition, Millett is one of the leading authorities on superior capsular reconstruction for irreparable cuff tears, having published on both technique and rehabilitation. Again, his results are good and primarily due to his expert execution.

For me, the main pulling factor for this visit though was to learn about Dr Millett's CAM procedure. The procedure, which he spent 5 years perfecting, is more than just a debridement of the GHJ. It includes a stepwise approach to decompress the joint and address all the pain-generators in order to provide increased pain-free movement. After debriding degenerate cartilage and synovitis, removing loose bodies and performing a SAD, he reshapes the deformed humeral head and excises inferior 'goat's beard' osteophytes to increase movement. While the latter allows indirect decompression of the axillary nerve (which innervates the antero-inferior GHJ), he also performs careful direct decompression of the nerve. The capsule is then extensively released to further improve range before any biceps tendinopathy is addressed. In young active patients with significant OA, he achieves an 85% survivorship at 2 years and apparently similarly commendable results at 5 years.

Despite his obvious abilities and success, Dr Millett and his team were hospitable, kind and generous, making me feel welcome throughout. He gifted me two books he had written on upper limb surgery, writing heart-felt messages in both, and the career advice he gave me was an honour to receive.

PROF GEORGE ATHWAL, ROTH / McFARLANE HAND AND UPPER LIMB CENTRE
(LONDON, ONTARIO, CANADA)

Following Vail, I made my way to 'the other London' in Ontario. The Roth / McFarlane Hand & Upper Limb Centre is understandably one of the leading upper limb units in North America. While my intention was to visit Prof Athwal, the reputation of the other surgeons there was also a massive pull, particularly that of Graham King, thought of as one of the Gods of elbow surgery.

The public sector service had very similar issues to those we have in the UK. While the latest high-spec technologies are available, traditional equipment is enough to get them over the line. I spent time in clinic observing detailed shoulder and elbow examinations but the majority of my time was again spent in theatre. While the service is predominantly 'cold', upper limb trauma is still referred in and squeezed onto elective lists as required.

I had the good fortune of seeing Dr King, one of the world's leading elbow surgeons, internally fix radial head and coronoid fractures followed by repair of the LCL for an elbow terrible-triad. The complex case was made to look straightforward with his stepwise approach, using a posterior incision, lateral approach to the elbow and a targeting device to capture the coronoid fragment with two screws. He also methodically took me through his elbow arthroscopy technique for instability. Again, his logical approach made it easy to both comprehend and replicate (Figure 3).

With Prof Athwal, my aim was to absorb some of his wisdom on shoulder arthroplasty and instability. When I saw him lecture in Nice last year, it was clear his practice was heavily influenced from his work in France. Having done an observership in France myself, I was keen to understand how the European experience enhanced his service.

With regards to arthroplasty, all cases receive pre-operative radiographs and CT with 3D reconstruction, the latter defining glenoid bone stock and anatomy. With all cases, he uses templating software to work out implant orientation and bone-graft requirements. With beach-chair positioning and through the deltopectoral approach, bone-graft is harvested from the humeral head using the BioRSA technique. After achieving adequate glenoid exposure, the graft is secured to the glenoid baseplate before attachment to the scapula in the pre-planned orientation. The proximal humerus is then prepared before the remaining anatomic or reverse-geometry components are inserted.

In revision cases, specialised implant-defining software is also utilised in conjunction with CT. This enables 3D depiction of the present implant in its actual position within the bone in a significantly more transparent format than traditional CT allows due to metal artefact (Figure 4). This information would otherwise only be attained in any accuracy at the time of surgery and therefore allows more accurate pre-operative planning of bony cuts, implant orientation and bone graft requirements for these more complex cases.

With regards to instability, Athwal's preference of the Latarjet over soft tissue Bankart repairs is based on several biomechanical studies he himself carried out and published after his time in France. Rather than accepting advice from senior surgeons, his efforts to evidence and reproduce this superiority himself is admirable. His meticulous approach along with his vast experience is no doubt why he attains excellent results with this method.

Similarly to Dr Millett, despite his achievements in shoulder surgery, Prof Athwal's willingness to teach, give advice and kindness seemed limitless. He invited me to his house for dinner where I met his delightful family. At work, every case was an opportunity to share his knowledge and experience for which I am very grateful.

SUMMARY

To have the opportunity to visit two of the worlds most respected and skilled shoulder surgeons was invaluable. The knowledge gained from these placements

regarding management of cuff tears, GHJ OA and instability will no doubt be utilised to better my practice. Both surgeons have continued to be in contact with me since my visit to North America with advice and encouragement. The contacts I have made are priceless.

PHOTOS (1-4):

Figure 1: Myself with (A) Prof George Athwal & (B) Dr Peter Millett

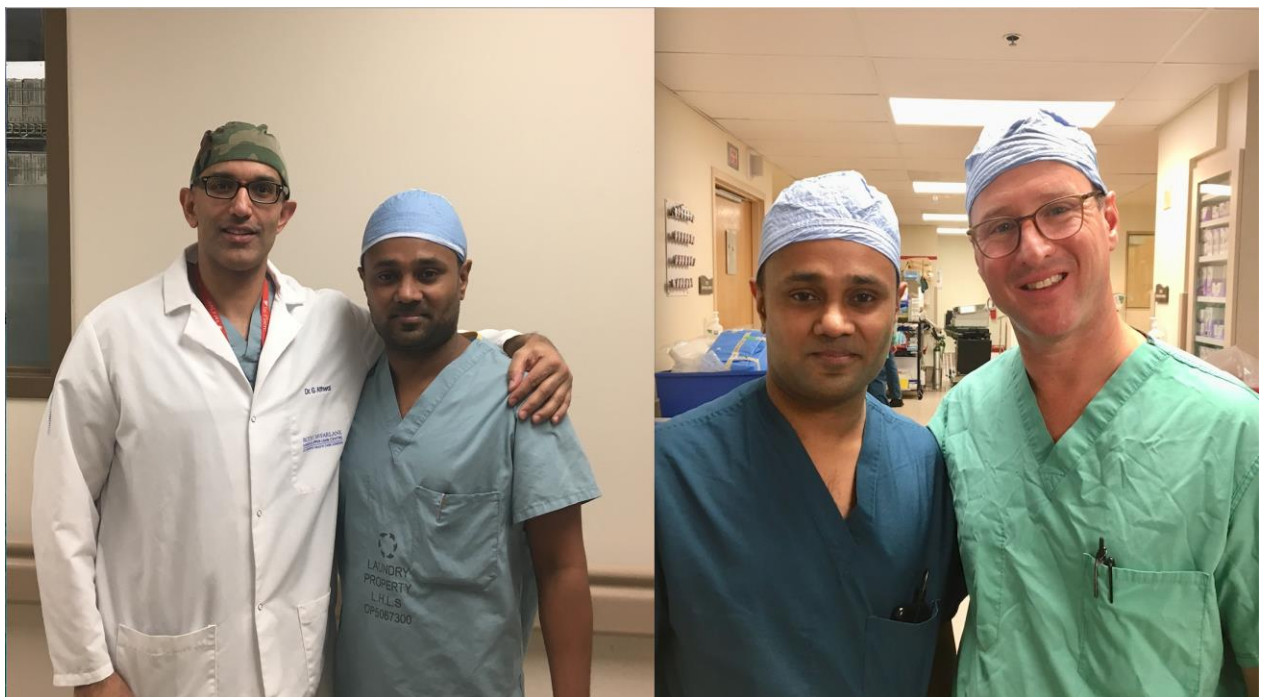

Figure 2: Meticulous cuff debridement & footprint preparation with microfracture

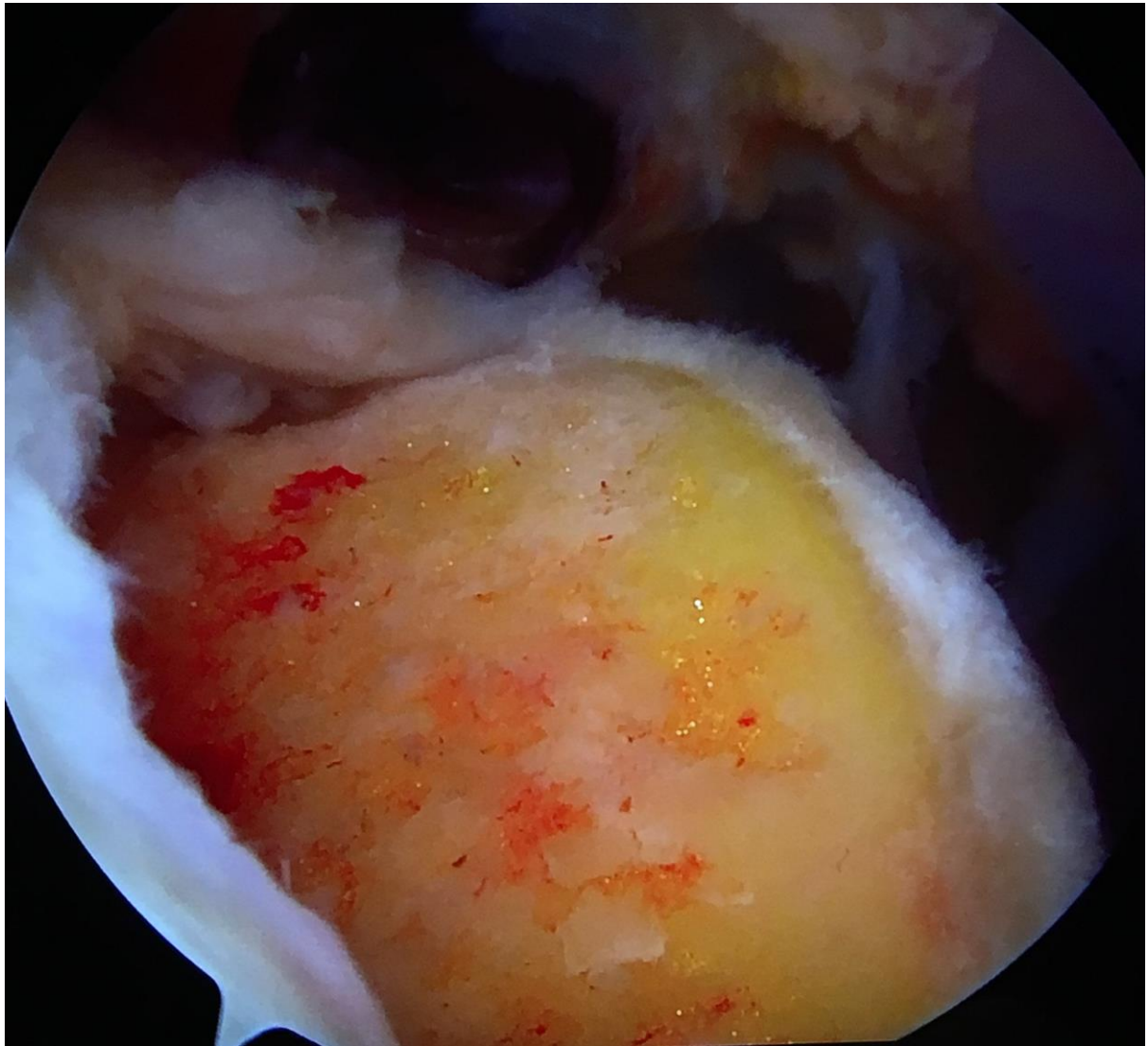


Figure 3: Dr Graham King demonstrating elbow arthroscopy

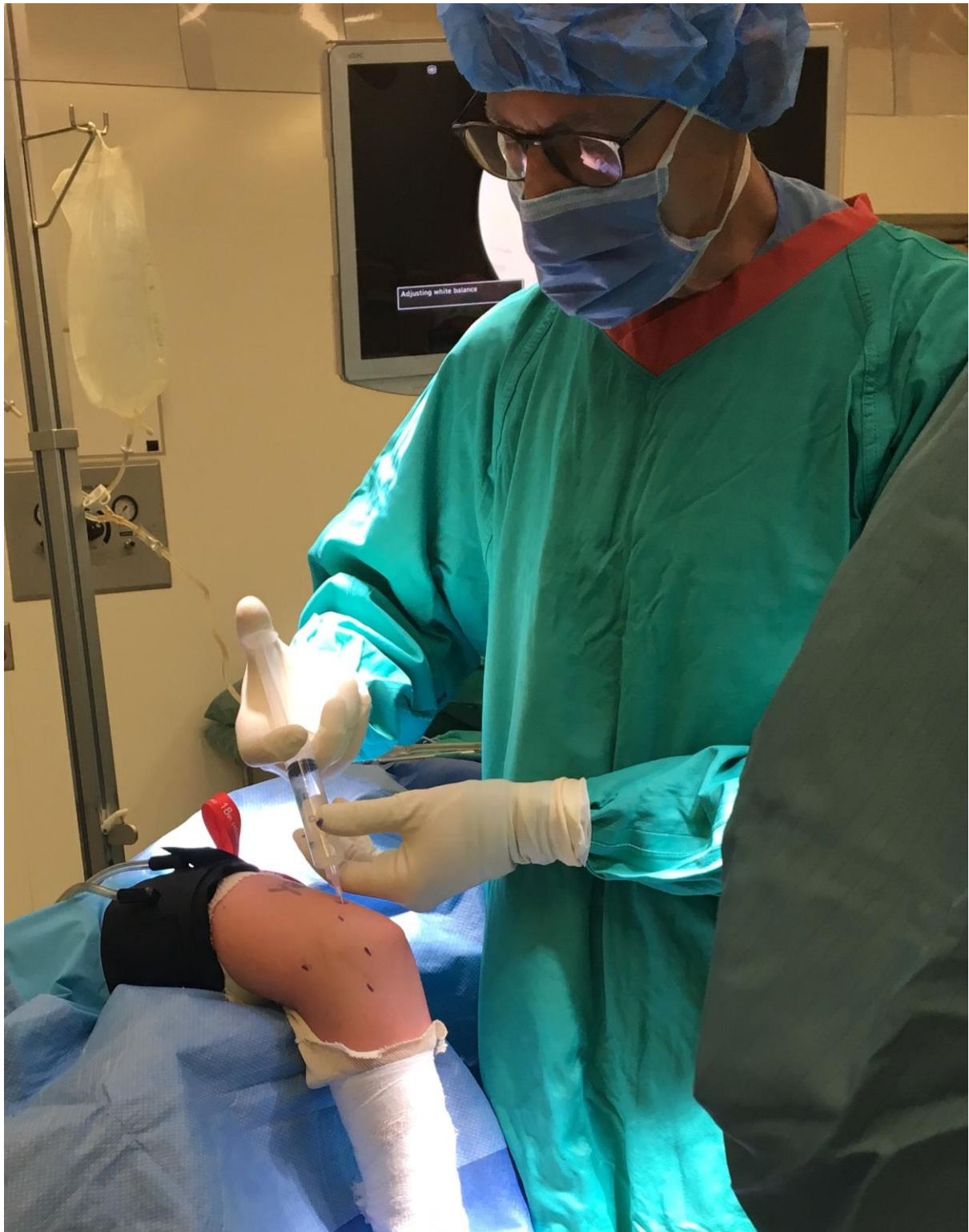

Figure 4: CT with implant enhancing software

