

# Trapeziectomy with a Capsular Suspension Flap is Associated with Reduced Post-Operative Pain

O. Jones, M. Dyer, Z. Hussain, L. Alsadoun, S. Mulgrew, N. Sheppard  
Plastic Surgery Department, Norfolk and Norwich University Hospital

## Background

The capsular suspension flap is a technique used to reconstruct the space between the base of the first metacarpal and scaphoid bone remaining following trapeziectomy first described by Rai in 2009<sup>[1]</sup>. This technique steers the thumb into an adducted posture, interposes soft tissue within the defect, and secures the first metacarpal base without the need for additional donor site morbidity.

A Cochrane review in 2015<sup>[2]</sup> compared different trapeziectomy techniques and found no evidence of differences in function or post-operative pain between techniques. However, this review did not include the trapeziectomy with a capsular suspension flap.

## Aim

To assess if there were any differences in post-operative outcomes when comparing trapeziectomy with a capsular suspension flap to simple trapeziectomy.

## Methods

All trapeziectomy cases from 1st January 2015 – 31st December 2019 were included. Operation and occupational therapy notes were reviewed for pre- and post-operative measurements of grip strength, pinch strength, visual analogue scale (VAS) pain score, QuickDASH, Patient Evaluation Measure (PEM) Hand and PEM Overall.

Data interpretation was performed using GraphPad Prism and the unpaired t-test with Welch's correction was used to compare the two groups.

## Results

Our patient demographics are given in Table 1.

Trapeziectomy with a capsular suspension flap demonstrated a greater average reduction in VAS pain score post-operatively when compared to simple trapeziectomy, and this change was statistically significant ( $p = 0.0412$ ).

Visual analogue scale (VAS) pain score is a subjective pain measurement tool commonly used in a number of MSK conditions. There a number of different formats to using this scale, though it is commonly scaled from 0-100 as was done in these assessments.

No other statistically significant differences in grip strength, pinch strength, QuickDASH or PEM scores was found.

## Conclusion

This is the first study to the authors' knowledge that evaluates the post-operative outcomes of patients undergoing trapeziectomy with a capsular suspension flap reconstruction. We report a statistically significant improvement in post-operative pain, but no significant difference in patient-reported or objective functional outcome measures. Our study is limited by its retrospective design, small patient numbers, and relatively short follow-up period. We suggest further evaluation of this technique is required through prospective randomised trials.

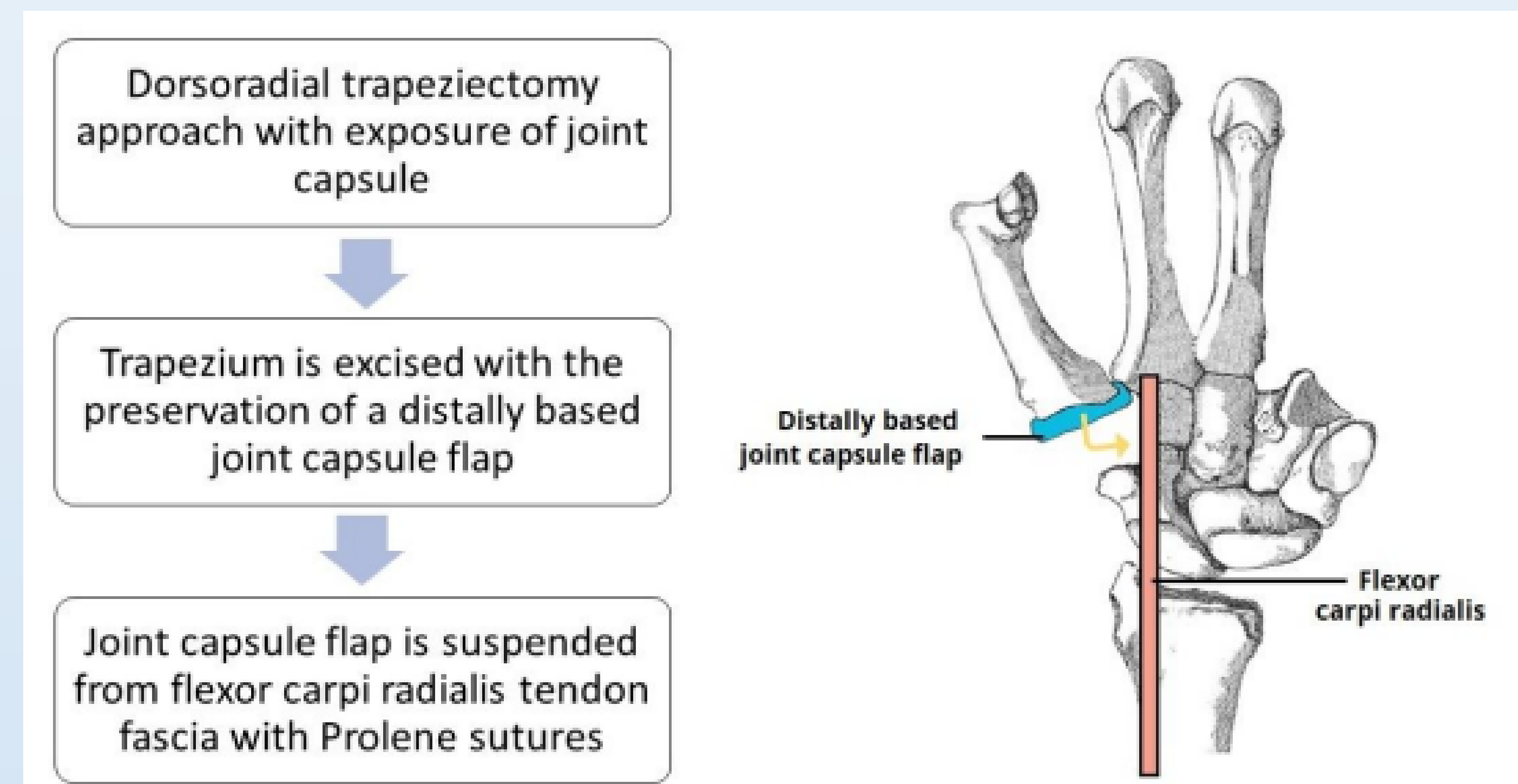


Figure 1 - Trapeziectomy with a capsular suspension flap. This schematic demonstrates a volar view of the hand following excision of the trapezium. A distally based flap of dorsal joint capsule is then sutured to the flexor carpi radialis.

	Simple Trapeziectomy	Trapeziectomy with Capsular Suspension Flap
<b>Cohort size</b>		
Number (n)	29	69
<b>Sex</b>		
Male, n (%)	2 (6.9)	11 (15.9)
Female, n (%)	27 (93.1)	58 (84.1)
<b>Age (Years)</b>		
Mean (range)	67.6 (55-78)	65.5 (47-88)
<b>Follow-up time (Days)</b>		
Mean (range)	143.2 (55-314)	127.1 (40-672)

Table 1 – Study Participants: Baseline demographic and clinical characteristics of patients undergoing simple trapeziectomy of trapeziectomy with a capsular suspension flap

Group	Average reduction in VAS pain score
Trapeziectomy with capsular suspension	4.4
Simple trapeziectomy	1.6

Table 2 – Visual Analogue Scale (VAS) pain scores: average reductions in VAS pain score of both patient groups

## References

1. Rai JK. Technical Notes and Tips: Trapeziectomy with a Capsular Interposition Flap. Ann R Coll Surg Engl 2009;91:345. <https://doi.org/10.1308/RCSANN.2009.91.4.345>.
2. Wajon A, Vinycomb T, Carr E, Edmunds I, Ada L. Surgery for thumb (trapeziometacarpal joint) osteoarthritis. Cochrane Database Syst Rev 2015;2017. <https://doi.org/10.1002/14651858.CD004631.PUB4>.