

Glenohumeral Osteoarthritis

1. Introduction

1.1 Definition

Degenerative shoulder (Glenohumeral) osteoarthritis is characterised by degeneration of articular cartilage and subchondral bone with narrowing of the glenohumeral joint. It causes significant pain, functional limitation and disability with an estimated prevalence of between 4% and 26%. (1)

1.2 Shared decision making

The General Medical Council's 'Good Medical Practice – duties of a doctor' guide [2] clearly states in the section on working in partnership with patients that doctors should:

- Listen to patients and respond to their concerns and preferences
- Give patients the information they want or need in a way they can understand
- Respect patients' right to reach decisions with the doctor about their treatment and care
- Support patients in caring for themselves to improve and maintain their health

This can only be achieved by direct consultation between the patient and their treating clinician. Decisions about treatment taken without such direct consultation between patient and treating clinician are not appropriate, as they do not adhere to principles of good medical practice.

1.3 Continuity of care

Continuity and co-ordination of care are essential parts of the General Medical Council's Good Medical Practice guidance.(2) It is therefore inappropriate for a clinician to treat a patient if there is no clear commitment from that clinician or the healthcare provider to oversee the complete care pathway of that patient including their diagnosis, treatment, follow-up and adverse event management.

1.4 Background

The prevalence of shoulder complaints in the UK is estimated to be 14%, with 1–2% of adults over the age of 45 consulting their general practitioner annually regarding new-onset shoulder pain [3]. Shoulder osteoarthritis is the underlying cause of shoulder pain in 2% to 5% of this group, although few truly population-based studies have been done. [1,4]

Painful shoulders pose a substantial socioeconomic burden. Disability of the shoulder can impair ability to work or perform household tasks and can result in time off work [4,5]. Shoulder problems account for 2.4% of all general practitioner consultations in the UK and 4.5 million visits to physicians annually in the USA [6,7]. The annual financial burden of shoulder pain management has been estimated to be US\$3 billion [8].

2. Glenohumeral arthritis - Pathway of Care

2.1 Aims of treatment

The overall treatment aim for shoulder osteoarthritis is to relieve pain and improve function. Treatment success needs to be defined individually with patients in a shared decision making process.

2.2 Pre-Primary Care (at home)

For causes of glenohumeral shoulder pain, there is potential for simple patient self-management strategies and prevention strategies at home prior to the need for a GP consultation, but research to develop and assess the impact of such strategies would be needed.

2.3 Assessment in primary care & Community Triage Services

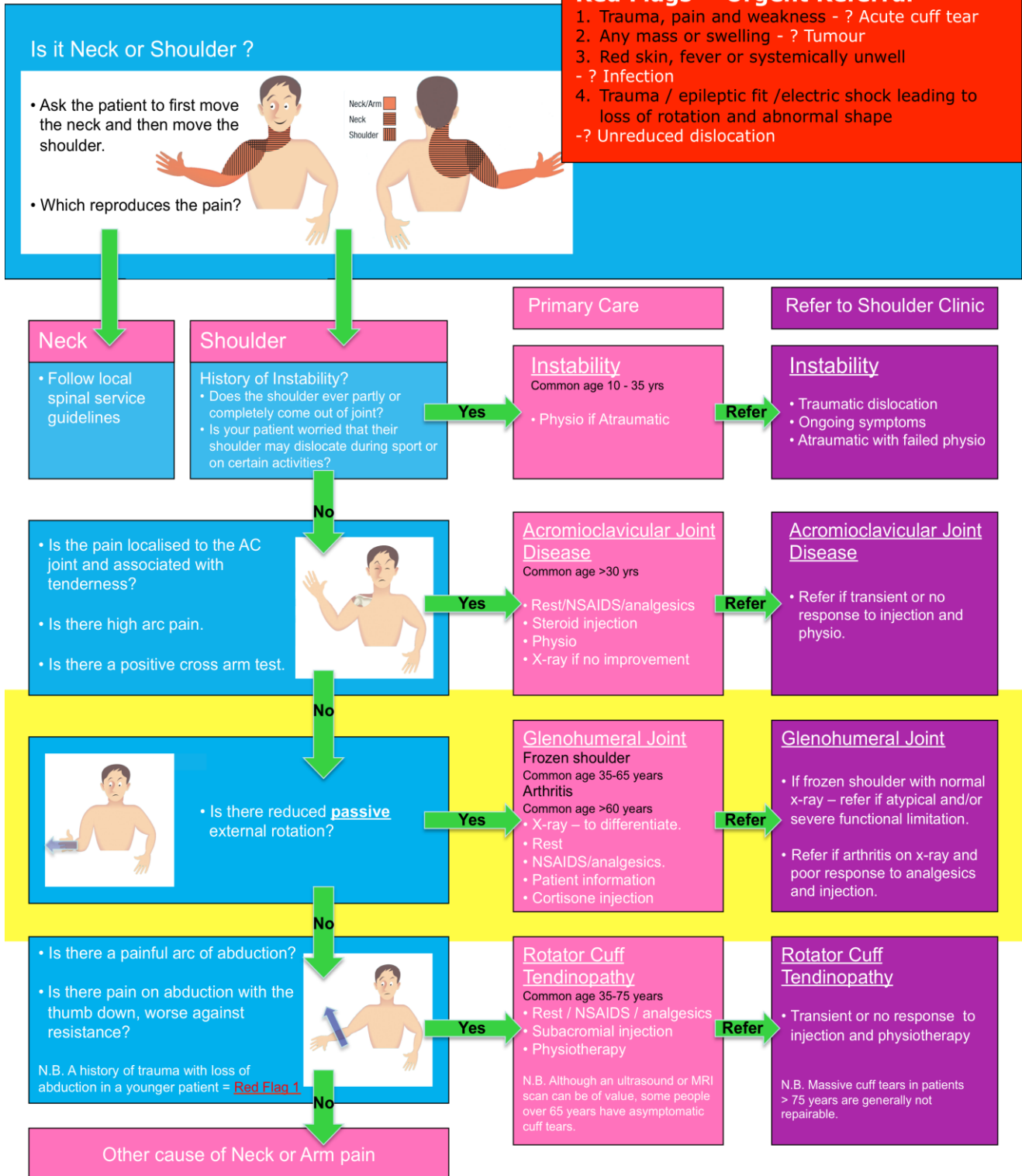
Diagnosis is based on History and Examination (***see and work through the Algorithm below to reach the relevant management recommendation***)

Making the correct diagnosis is crucial, and will ensure an efficient and optimum treatment for the patient. Plain radiographs of the shoulder are essential for confirming the diagnosis. True Anteroposterior view (in scapular plane) and Axillary view are recommended for this purpose. Specialist imaging such as MRI or CT scans are not indicated for treatment of glenohumeral OA in primary care.

Diagnosis of Shoulder problems in Primary Care: Guidelines on treatment and referral

Red Flags = Urgent Referral

1. Trauma, pain and weakness - ? Acute cuff tear
2. Any mass or swelling - ? Tumour
3. Red skin, fever or systemically unwell - ? Infection
4. Trauma / epileptic fit / electric shock leading to loss of rotation and abnormal shape - ? Unreduced dislocation



© Oxford University: AJ Carr, JL Rees.

The British Elbow and Shoulder Society supports
Best Practice Patient Pathways for the Shoulder

Features of Importance are;

- Hand dominance
- Occupation and level of activity or sports
- Location, radiation and onset of pain
- Duration of symptoms
- Global reduction in range of motion, especially severe loss of passive external rotation in the affected shoulder with arm by the side
- History of multiple joint involvement or systemic manifestations
- X-rays to confirm glenohumeral arthritis, avascular necrosis or dislocation of the shoulder, which produce a similar clinical picture. X-rays are essential if there is history of significant trauma.

2.4 Red Flags for the Shoulder

Acute severe shoulder pain needs proper and competent diagnosis. Any shoulder 'Red Flags' identified during primary care assessment needs urgent secondary care referral.

- A suspected infected joint needs same day urgent referral.
- An unreduced dislocation needs same day urgent referral.
- Suspected malignancy or tumour needs urgent referral following the local two-week cancer referral pathway.
- Suspected inflammatory oligo or poly-arthritis or systemic inflammatory disease should be considered as a 'rheumatological red flag' and local rheumatology referral pathways should be followed.

2.5 Treatment in Primary Care & Community Triage Services

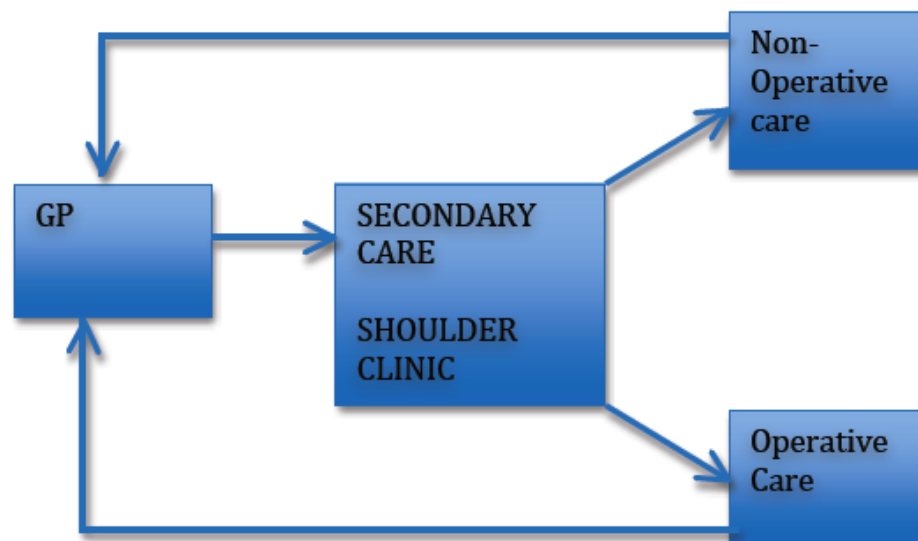
- Treatment depends on the severity of symptoms and degree of restriction of work, domestic and leisure activities. The aims of treatment are:
 - Pain relief
 - Improving range of motion
 - Reducing duration of symptoms
 - Return to normal activities
- Following interventions are suitable for primary care:
 - Analgesics / NSAIDs
 - Local injections
 - Acupuncture
 - Physical Therapy
- This is a painful and debilitating condition, where the pain is often severe. The onset of stiffness is progressive over many years and will cause significant functional deficit, typically presenting in patients over 60 years of age, where 32% of patients have been

reported to have shoulder arthritis. [26] Treatment should be tailored to individual patients' needs depending on response and severity of symptoms.

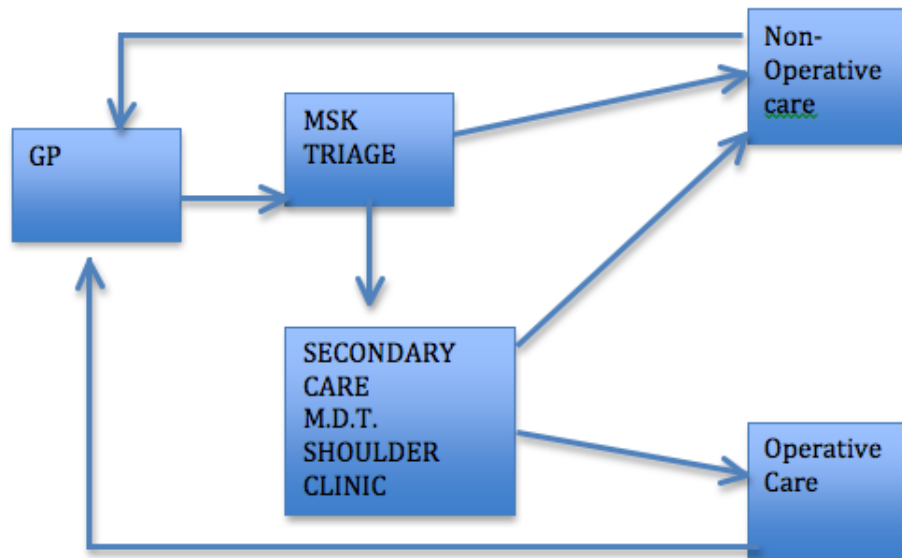
- Beware of red flags such as tumour, infection, unreduced dislocation, or inflammatory polyarthritis.
- Most patients with established osteoarthritis will respond poorly to conservative treatment. The most frequent indications for invasive treatments are pain and persistent and severe functional restrictions that are resistant to conservative measures.
- Failure of functional adaptation should trigger referral for consideration of surgical options.
- Shared decision-making is important, and individual patients' needs are different. Failure of initial treatment to control pain, if degree of stiffness causes considerable functional compromise, or if there is any doubt about diagnosis, prompt referral to secondary care is indicated.

2.6 Example of models of referral pathways currently used in the NHS

Standard Model



Alternative Model



2.7 Secondary Care

- In a UK study of patterns of referral of shoulder conditions, 22% of patients were referred to secondary care up to 3 years following initial presentation, although most referrals occurred within 3 months [9].
- Confirm diagnosis with history and examination
- Obtain imaging with plain radiographs to confirm diagnosis of glenohumeral osteoarthritis and to rule out other differentials such as avascular necrosis of humeral head (without arthritis) or dislocation. Specialist imaging with Ultrasound, CT or MRI scans may be indicated for evaluation of the state of the rotator cuff and bone stock as well as to aid preoperative planning.
- Counsel patient fully regarding operative and non-operative options
- Ensure multidisciplinary approach to care with availability of specialist physiotherapists and shoulder surgeons
- The following non-surgical interventions maybe considered in secondary care for temporary alleviation of symptoms, for example where surgery is not desired, contraindicated or needs to be delayed:
 - Autologous platelet preparations
 - Sodium hyaluronate therapy
 - Nerve blocks or local injections

- If symptoms fail to resolve with conservative treatment then arthroscopic or open surgical interventions may be considered. This choice depends mainly on clinical indication and surgical expertise.
- Surgical secondary care interventions include:
 - Arthroscopic interventions including debridement with or without biological resurfacing.
 - Biological glenoid resurfacing with hemiarthroplasty
 - Hemiarthroplasty (including resurfacing)
 - Total Shoulder Replacement (TSR)
- Arthroscopic debridement is performed under general anaesthesia. The surgery aims to remove loose bodies, osteophytes, treat damage to articular cartilage with microfracture techniques and release the contracted capsule. This potentially may reduce pain and improve range of movement. This procedure may be appropriate for younger patients with early arthritis.
- Suprascapular nerve block is a purely pain relieving intervention. It is thought that the suprascapular nerve is sensory to the shoulder capsule and nerve block therefore reduces symptoms of pain. This intervention is NOT an alternative to shoulder replacement for definitive treatment of arthritis.
- Biological Glenoid Resurfacing is a technique used particularly in younger patients. This can be in conjunction with a shoulder hemiarthroplasty in order to avoid the insertion of a glenoid component. The technique can also be performed arthroscopically. Described methods include the use of biological material, for example meniscal allograft or semi-synthetic material using typically human dermis or alternative xenografts as an interposition arthroplasty, glenoid microfracture or a “ream and run” glenoid debridement technique.
- Hemiarthroplasty, Total Shoulder Replacement, Reverse Shoulder Replacement are arthroplasty procedures performed under general anaesthesia with or without regional anaesthesia. Hemiarthroplasty includes stemmed, stemless and resurfacing implants. Hemiarthroplasty addresses only the humeral arthritis. In contrast Total Shoulder and Reverse Shoulder Replacements address arthritis on both humeral and glenoid sides of the joint. Total Shoulder Replacement is used for patients with an intact rotator cuff whereas Reverse Shoulder Replacement is reserved for patients with cuff tear arthropathy or older patients with cuff insufficiency.
- It would be expected that surgical units performing surgery for shoulder OA:

- Ensure patients undergo appropriate pre-operative assessment to ensure fitness for surgery and to confirm discharge planning.
- Perform surgery in appropriately resourced and staffed units.
- Have access to specialist anaesthesia services including availability of nerve blocks for post-operative pain relief
- Have radiology services available during the peri-operative period
- Have arrangements for adequate post-operative physiotherapy and appropriate follow-up as clinically indicated
- Have suitable resources to manage surgical and medical complications

2.8 Linked Metrics

Arthroscopic Debridement

- Diagnosis Codes M19.0, M19.1, M19.2
- Procedure Codes (OPCS 4.7) - Y76.7, W80.8, W80.9

Hemiarthroplasty of head of humerus

- Diagnosis Codes M19.0, M19.1, M19.2
- Procedure Codes (OPCS 4.7) W49.1, W49.4, W49.8, W50.9, W51.1, W51.8, W51.5, W51.8, W51.9

Total prosthetic replacement of shoulder joint

- Diagnosis Codes M19.0, M19.1, M19.2
- Procedure Codes (OPCS 4.7) W96.1, W96.8, W97.1, W97.8, W97.9, W98.1, W98.8, W98.9, W49.9, W50.1, W50.4, W50.8,

Hybrid prosthetic replacement of shoulder joint

- Diagnosis Codes M19.0, M19.1, M19.2
- Procedure Codes (OPCS 4.7) 006.1, 006.8, 006.9, 007.1, 007.8, 007.9, 008.1, 008.8, 008.9

2.9 Outcome Metrics

- Length of stay
- Re-admission rate within 90 days
- PROM pre-procedure, and minimum 6 months post procedure
- Infection / other adverse events
- Revision of prosthetic replacement

2.10 Research & Audit

- Patient Reported Outcome Measures - A validated clinical score, preferably a patient reported outcome measure (PROM), should be used preoperatively and following treatment.
- Acceptable scores include Disability of Arm, Shoulder and Hand [DASH], Constant score and the Oxford Shoulder Score (OSS). Other measures like EQ5D may be used for economic analysis.
- Scores should be captured preoperatively and minimum six months following intervention, which allows longitudinal analysis to determine magnitude of treatment effect and consequences of any treatment related adverse events.
- Arthroplasty or replacement procedures should be entered onto the National Joint Registry (NJR) in order to monitor outcomes, complications and longer-term survivorship of implanted prostheses.

2.11 Patient/Public/Clinician Information

- Patient and public information – ensure all available information is provided regarding the benefits and risks of all treatment options.
- Clinician information - ensure access to available evidence.

3. Evidence – Shoulder Osteoarthritis

3.1 Evidence for effectiveness and cost effectiveness of non-invasive treatment

It is important to note that the evidence to support conservative treatments and the advantages between different treatments remains limited. Until evidence becomes available, clinical and shared-decision making on accessing available interventions is based on level of symptoms and functional restrictions is recommend.

Additionally the effectiveness of many non-invasive interventions have been investigated in terms of improvement in shoulder pain in relation to the entire spectrum of shoulder conditions. Therefore despite not being proven to be effective in the management of shoulder arthritis specifically, such interventions as acupuncture or injections maybe effective in symptom control from arthritis as opposed to management of the disease process itself.

Oral drug treatment

There is strong evidence for the use of oral Paracetamol given regularly to modify the pain caused osteoarthritis in general. [10] Paracetamol is safe and has a minimal adverse effect profile. NSAIDs also have proven effectiveness in the management of osteoarthritis in general, as they reduce pain associated with inflammation and synovitis, but they are not recommended as first-line medication due to significant adverse effect profile. [11] Likewise, opiate-based analgesia, although shown to be effective for pain relief, is not recommended for long-term use due the adverse effect profile and the risk of dependence. [12]

Sodium Hyaluronate injection

Blaine et al. published a randomised controlled trial comparing the use of weekly saline injections for five weeks with a series of three or five Sodium Hyaluronate injections for shoulder pain. Patients had multiple pathologies, but of the 660 patients enrolled in the study 398 had osteoarthritis. The study found statistically significant improvement in VAS scores at 7 and 26 weeks time points in patients with shoulder arthritis with/without rotator cuff tear. However the maximum follow-up period was 26 weeks and thus no data is available in the longer term. [13]

Additionally Merolla et al. completed a retrospective cohort study comparing the outcome of two cohorts undergoing glenohumeral injection for shoulder arthritis. 41 and 51 patients had received corticosteroid therapy and hyaluronate therapy respectively. Those patients in the hyaluronate group had statistically better VAS, Constant-Murley and SPADI scores in comparison to pre-intervention scores at time points 1,3 and 6 months. In contrast, patients in the corticosteroid group had no improvement after one-month post injection for any parameters. [14]

Corticosteroid Injections

There is no evidence to support the routine use of Corticosteroid injections for the management of shoulder arthritis. [15] What evidence supporting the use of such agents comes from the literature relating to the treatment of knee osteoarthritis. However as above, Corticosteroid injections may have a short-term effect of up to one month, which could make them useful as a diagnostic aid when shoulder arthritis presents with concomitant pathology.

Autologous platelet preparations

There is no evidence to support the use of platelet gel or platelet-poor products in the management of shoulder arthritis. Again evidence for the use of these products comes from the literature relating to the management of knee osteoarthritis, of which Level 1 evidence is present. [16] Clinical trials comparing the using of Platelet-Rich Plasma (PRP) preparations with Hyaluronic acid preparations have shown superior outcome in terms of pain relief, reduction in stiffness and functional improvement in the PRP group, with follow-up of up to 24 months. [17] It is thought that these agents allow tissue generation and growth, through a process of inflammation, cell proliferation and remodeling. This treatment method may be the focus of future research with the development of well-designed clinical trials specific to the non-operative management of shoulder osteoarthritis.

Acupuncture

Lathia et al conducted a randomised controlled trial looking at the role of Acupuncture in the treatment of chronic shoulder pain. The groups included a control versus two different forms of acupuncture. The patients in the acupuncture groups had statistically significant improvement in SPADI scores. [18] However the patients had a variety of pathologies; for example, frozen shoulder, impingement syndrome, rotator cuff tears so the results cannot be extrapolated to recommend the use of acupuncture in shoulder arthritis.

Suprascapular nerve block or ablation

Several studies have demonstrated short-term benefit from Suprascapular nerve block for a variety of shoulder conditions, including shoulder osteoarthritis, frozen shoulder, rheumatoid arthritis, rotator cuff tears, for example. Most studies have demonstrated improvement of up to 12 weeks post intervention. In cases of arthritis this maybe diagnostic but as the injection is relatively safe this can be repeated if required. Although evidence for these interventions is limited to case series there are several studies in the literature, therefore Suprascapular nerve modulation is useful in the management of shoulder symptoms, in the short-term in most cases. [19] Suprascapular nerve ablation is not indicated and should not be performed for glenohumeral osteoarthritis with an intact rotator cuff.

3.2 Evidence regarding the effectiveness of surgery

Arthroscopic Debridement

Namdari et al. conducted a literature review on the role of Arthroscopic Debridement in the management of shoulder arthritis. After exclusions only five papers were deemed suitable for analysis all of which were appraised at level IV evidence. 245 shoulders in total were included. Patients reported statistically significant improvement in range of motion from forward flexion of 136 degrees and 36 degrees external rotation to 159 degrees and 58 degrees respectively. Functional outcome, satisfaction and pain scores used differed between series included in the review but had improved in all series included in the study. 13% of patients from all included series were “converted” to a shoulder arthroplasty procedure at a mean of 13 months. [20] The study concluded the arthroscopic management does not have enough quality evidence to support its routine use. However due to the short-term benefit of reduced pain and improved function it maybe useful in a younger cohort of patient looking for joint-preserving options for advanced GHJ OA. [21]

Shoulder replacement surgery is an established and effective surgical treatment for glenohumeral arthritis. Hemiarthroplasty or TSR provides significant improvement in pain, global health assessment, function and quality-of-life scores which has been demonstrated in the medical literature. [22,23,24] These benefits are comparable to other surgical treatments in Orthopaedic surgery e.g. Total Hip Replacement and other interventions in medicine generally including Coronary Artery Bypass Grafting. [25]

Biological Glenoid Resurfacing with or without hemiarthroplasty

Namdari et al. performed a systematic review to critically examine the outcomes of Biologic Glenoid Resurfacing in the treatment of glenohumeral osteoarthritis. Seven level IV case series were included in the review, 128 patients underwent Glenoid Resurfacing with Hemiarthroplasty and 52 patients underwent Arthroscopic Glenoid Resurfacing giving a total of 180 patients. Mean age was 46. Preoperative indications for resurfacing were multiple and not limited to primary osteoarthritis. There were no control groups in any of the studies chosen. Patients were followed up for a mean of 46.6 months. Outcome measures reported were multiple with no uniformity amongst studies. Statistically significant improvements were found in most outcome measures evaluated post-operatively which indicated resurfacing can be successful short term, however, little evidence exists on long term results. The overall complication rate was 13.3% and reoperation rate was 26%, higher than reported values for other treatment options. It is suggested that Biological Glenoid Resurfacing could be a good alternative treatment for young patients with glenohumeral arthritis as it avoids many of the concerns associated with TSR in that age group. They found that due to the quality of the primary studies and inconsistencies in reporting outcomes it is not possible to draw meaningful conclusions to confirm or refute this. None of the studies evaluated compared resurfacing to other treatments.

Many patients had already undergone at least one previous shoulder surgery prior to resurfacing and it is not clear what influence this may have on outcome, complications and reoperation rates. All studies lacked the power to define outcomes based on individual etiologies for resurfacing. [26]

Additional case series focusing on biological resurfacing have consistently produced unsatisfactory longer-term results, using a variety of materials including dermal and meniscal allografts. Puskas et al reported an 83% revision rate with dermal allograft at a mean of 16 months. [27] In the meniscal group the revision rate was 60% at 22 months. Similarly Hammond et al. compared the results of two cohorts of patients, one having undergone hemiarthroplasty and the second hemiarthroplasty with biological resurfacing. The revision rates were 26% and 60% respectively. [28]

Current evidence does not support the use of Biological Glenoid Resurfacing using interposition arthroplasty for shoulder osteoarthritis, with or without the use of Hemiarthroplasty .

Microfracture of the glenoid and humerus have demonstrated improvement in pain and function for focal cartilage defects. [27] The greatest improvement was in small defects on the humeral side, with less benefit for lesions on both sides of the glenohumeral articulation. Microfracture replaces normal articular cartilage with fibrocartilage, as demonstrated by studies in the knee. Although there is evidence to support microfracture, there is currently no evidence supporting glenoid microfracture in conjunction with Hemiarthroplasty. [28]

Reaming techniques of the glenoid in younger patients of less than 55 years of age have demonstrated improvements in pain and function when utilised with Hemiarthroplasty. Concentric reaming as described by Saltzman et al. in 65 patients showed improvement in pain and function. [29] Similarly Clinton et al, published a case-control study with 35 patients comparing a “ream and run” technique with Total Shoulder Replacement, demonstrating similar improvement in pain and function in both patient groups. [30]

Humeral Head Resurfacing

Humeral Head Resurfacing has been shown in multiple case series to reduce pain and improve function in patients with osteoarthritis of the glenohumeral joint. Maximum follow up in these series extends to a mean of 28 years (21- 40 years) (31). Although glenoid access may be difficult to achieve without humeral head removal Total Shoulder and Hemiarthroplasty have been reported using Resurfacing in osteoarthritis with similar results reported at 7 years in a population group of mean 72 years old (32). In the longer term glenoid erosion, as with other forms of Hemiarthroplasty (stemmed and stemless) may be seen and has been reported in 12% at 4 years radiologically (33).

The cumulative 5-year revision rates following humeral resurfacing from the Australian (35) and Danish arthroplasty registers (36) have been reported as 11.2% and 9.9% respectively. The Danish report however makes the following observation "The difference in the rate of revision between resurfacing hemiarthroplasty and stemmed hemiarthroplasty may also be influenced by the fact that the resurfacing procedure can be more easily revised than other designs of arthroplasty. This will thus favour other designs when the rates of revision are compared"

Resurfacing has been recommended particularly in younger patients to preserve bone stock where implanting a polyethylene glenoid prosthesis with potential wear and failure needs to be weighed against the potential long term risk of glenoid erosion sometimes seen in Hemiarthroplasty. [31,32,33,37]

Stemless Shoulder Replacement

Stemless Shoulder Replacement is the latest development to combat potential stem related problems in shoulder arthroplasty. The concept allows the resection of the humeral head to facilitate glenoid exposure in order to insert a glenoid prosthesis to perform a Total Shoulder Replacement which is more technically demanding in conventional surface replacement arthroplasty.

The number of stemless implants reported in the literature is small and follow up remains limited. All but one published case series available quote less than 4 years mean follow up, for both Hemiarthroplasty [38] and Total Shoulder Replacement. [38-40]. One report describes 39 patients treated for osteoarthritis with a mean follow up of 68 months showing similar results achieved using hemiarthroplasty and total shoulder replacement (41) In the short and medium term results reported of stemless arthroplasty seem comparable to conventional stemmed arthroplasty surgery.

Humeral resurfacing or Hemiarthroplasty versus TSR

Most of the literature on surgical interventions focuses on the debate about Total Shoulder Replacement versus resurfacing or stemmed Hemiarthroplasty.

Fevang et al [42] reported the outcomes of patients treated with shoulder arthroplasty using data from the Norwegian arthroplasty register. They observed significantly better functional and quality of life outcomes in patients with GHJ OA treated with TSR compared with either stemmed or resurfacing hemiarthroplasty. A shortcoming of this study was the response rate of 65%.

Rasmussen et al [43] compared the patient-reported outcomes and revision rates of Humeral resurfacing (RHA) with stemmed hemiarthroplasty (SHA) and TSR using data from the Danish shoulder arthroplasty register. They found that patients treated with TSR had better Western Ontario Osteoarthritis Index score (WOOS) at 1 year compared with RHA and SHA. There was no difference in the revision rate between the groups.

Stemmed Hemiarthroplasty versus Total Shoulder Replacement

Edwards et al. 2003 conducted a multi centre study comparing 601 TSRs to 89 Hemiarthroplasties. They compared constant score, active forward elevation, and external rotation, in patients with a minimum follow up of two years. They found that the functional outcome measures in those undergoing TSR were significantly better than those undergoing Hemiarthroplasty. They found no significant difference in pain scores between the two groups. However they reported a substantially higher revision rate in the TSR group explained by the use of metal-backed glenoid components in 238 patients. The overall revision rate at 7 years was 30% in the TSR group versus 4% in the Hemiarthroplasty group. [44]

Radnay et al. performed a systematic review and meta-analysis of 23 studies totaling 1952 patients, evaluating TSR and Hemiarthroplasty. Their findings showed that compared with Hemiarthroplasty, TSR provided statistically significant improvement in pain relief, forward elevation, external rotation and patient satisfaction. Revision rates were reported as 10.2% for hemiarthroplasties as opposed to 6.5% for TSR. 8.1% of Hemiarthroplasties required conversion to TSR due to pain, suggesting the glenoid progressively erodes over time resulting in worsening outcomes. In TSR the type of glenoid component employed appeared to have an impact on revision rates with 6.8% of TSR's with metal backed glenoids requiring revision compared with 1.7% of TSR's with all-polyethylene glenoids. The authors, however, noted a low level of evidence for the majority of studies evaluated (mean level of evidence 3.73) and therefore advised caution in any conclusions drawn. [45]

Lo et al. performed a prospective trial with 42 patients randomised to receive either TSR or Hemiarthroplasty. The patients were followed up for two years and assessed using a number of validated shoulder scores as well as a pain score. They found significant improvements in all domains for both patient groups but no statistical difference between TSR and Hemiarthroplasty groups. Of the 20 patients randomized to hemiarthroplasty, three patients had persistent pain from glenoid arthrosis and two of these were revised to a TSR whilst the third patient was considering revision within the two-year follow-up period. The shortcomings of the trial are low patient numbers and follow up length. [23]

Bryant et al. 2005 performed a systematic review and meta-analysis of 4 studies totaling 112 patients. Their findings were similar to those of Radnay et al. TSR showed a significantly better improvement over Hemiarthroplasty in the University of California, Los Angeles (UCLA) shoulder score, pain score and forward elevation. It is noted that all of the studies included in the review had design weaknesses and thus conclusions drawn should be approached with caution. [47]

Sandow et al [48] reporting on the results of a randomized study comparing hemiarthroplasty with TSR in patients with GHJOA with an intact rotator cuff at a

minimum follow-up of 10 years, observed that patients in the TSR group had less pain and better function at 2 years and there was no substantial deterioration in function at 10 years. Furthermore none of the hemiarthroplasty patients were pain-free at 10 years whilst approximately half the TSR patients were pain-free. The revision rate in the hemiarthroplasty group was 31% compared with 10% for the TSR group and revision of hemiarthroplasty to TSR was challenging due to glenoid erosion.

Singh et al. performed a Cochrane review on surgery for shoulder osteoarthritis. They included seven studies with 238 patients which were RCTs / quasi RCTs. Their reported findings were that TSR provided significantly better American Shoulder and Elbow Society (ASES) functional scores than Hemiarthroplasty. Pain and quality of life scores were however found not to be significantly different. It should be noted that this assumption was based on results from only one paper of the seven reviewed. [49] Equally revision rates were found to be higher with Hemiarthroplasty based on the findings of one paper.

Izquierdo et al. published an American Academy of Orthopaedic Surgeons guideline based on a thorough literature search. The quality of scientific data found on interventions for glenohumeral osteoarthritis was noted to be poor. Nineteen suitable studies were found which were used to formulate recommendations. Many interventions commonly used in clinical practice were found not to have any evidence of suitable quality to afford recommendation. Weak and moderate evidence was found to support the use of surgery. Weak evidence supported the use of TSR and Hemiarthroplasty. Moderate evidence was found to suggest TSR is preferable to Hemiarthroplasty in terms of improvement in global health assessment score and pain scores, however functional and quality of life outcomes were no different. [22]

Cemented versus Uncemented stems in Total Shoulder Replacement

Lichfield et al. performed a double blind, randomised controlled trial across seven tertiary centres in Canada to evaluate cemented vs. uncemented humeral components. 161 patients were randomised intraoperatively to receive either cemented humeral stem or uncemented press fit stem. The implant used was the same and patients were followed up for 2 years. The study showed that the group receiving a cemented stem had a significantly better Western Ontario Osteoarthritis of the Shoulder (WOOS) index. Two other outcome measures used did not detect any difference (McMaster-Toronto Arthritis Patient Preference Disability Questionnaire (MACTAR), ASES). Range of motion (ROM) and strength improvement was similar for both groups. Baseline epidemiological data was well matched apart from gender ratios of the two groups with more males in the cemented group and more females in the uncemented. It was suggested that the perceived benefits found in the cemented group may be gender specific towards males. It is of note that only one TSR went on to revision. [51]

Revision rates for Total Shoulder Replacement

Singh et al. used the Mayo Clinic Total Joint Registry to conduct a study on revision surgery following TSR. A total of 2588 joints were analysed between 1976 and 2008 with up to a twenty-year follow up. The study included TSR performed for a number of diagnoses, thus it is difficult to extract data pertaining solely to TSR performed for osteoarthritis. Osteoarthritis was the underlying diagnosis for 1640 joints of which 114 underwent revision over the twenty-year period. This equates to 81% of TSRs surviving twenty years. It is not possible from the study to define risk factors for the osteoarthritis group, however, it was generally found that male gender, underlying rotator cuff disease and tumour were associated with increased risk of revision. BMI and co morbidity was not found to increase revision risk [52].

3.3 OVERALL EFFECTIVENESS OF AVAILABLE TREATMENTS

3.3.1 ORAL DRUG TREATMENT

Likely to be beneficial

Oral Paracetamol
NSAIDs

3.3.2 LOCAL INJECTIONS

Likely to be beneficial

Sodium Hyaluronate
Suprascapular nerve block

Unknown Effectiveness

Platelet-derived products

3.3.3 NON-DRUG TREATMENT

Unknown Effectiveness

Acupuncture

3.3.4 SURGERY

Known effectiveness

Humeral Head Resurfacing
Hemiarthroplasty
Anatomical Total Shoulder Replacement (TSR)

Unknown effectiveness

Arthroscopic Debridement
Biological Glenoid Resurfacing

The scope of this review has been to produce evidence on the management of primary glenohumeral osteoarthritis.

Other aetiologies of shoulder arthritis include inflammatory, avascular necrosis, cuff failure and sequelae of trauma. Comprehensive review of the evidence in relation to these aetiologies is beyond the scope of this review but forms the basis of further development of evidence based care pathways.

References

- (1) Royal College of General Practitioners; Office of Populations, Censuses and Surveys. Third national morbidity survey in general practice, 1980-1981; Department of Health and Social Security, series MB5 No 1. London: HMSO.
- (2) Good Medical Practice:
http://www.gmc-uk.org/guidance/good_medical_practice.asp Access date: 26/12/2014
- (3) Urwin, M, Symmons, D, Allison, T, Brammah, T, Busby, H, Roxby, M, Simmons, A, Williams, G. Estimating the burden of musculoskeletal disorders in the community: the comparative prevalence of symptoms at different anatomical sites, and the relation to social deprivation, *Ann Rheum Dis*, 1998; 57: 649-655.
- (4) Harkness, EF, Macfarlane, GJ, Nahit, ES, Silman AJ and McBeth J. Mechanical and psychosocial factors predict new onset shoulder pain: A prospective cohort study of newly employed workers. *Occupational and Environmental Medicine* 2003; 60(11): 850-857.
- (5) Van der Windt D, et al. Occupational risk factors for shoulder pain: a systematic review. *Occupational and Environmental Medicine* 2000; 57(7): 433-442.
- (6) Linsell L, et al. Prevalence and incidence of adults consulting for shoulder conditions in UK primary care; patterns of diagnosis and referral. *Rheumatology* 2006; 45(2): 215-221.
- (7) Oh LS, et al., Indications for rotator cuff repair: a systematic review. *Clin Orthop Relat Res* 2007; 455(Feb): 52-63.
- (8) Van der Windt DA, K.B., Boeke AJ, Devillé W, De Jong BA, Bouter LM. Shoulder disorders in general practice: prognostic indicators of outcome. *Br J Gen Pract* 1996; 46(410): 519-523.
- (9) Linsell L, Dawson J, Zondervan K, Rose P, Randall T, Fitzpatrick R et al. Prevalence and incidence of adults consulting for shoulder conditions in UK primary care; patterns of diagnosis and referral. *Rheumatology* 2006; 45: 215-21.
- (10) Bijlsma JW. Analgesia and the patient with osteoarthritis. *Am J Ther*. 2002 May-Jun;9(3):189-97
- (11) Seed SM, Dunican KC, Lynch AM. Osteoarthritis: a review of treatment options. *Geriatrics*. 2009 Oct;64(10):20-9. Review

- (12) Jawad AS. Analgesics and osteoarthritis: are treatment guidelines reflected in clinical practice? *Am J Ther.* 2005 Jan-Feb;12(1):98-103.
- (13) Blaine T, Moskowitz R, Udell J, Skyhar M, Levin R, Friedlander J, Daley M, Altman R. Treatment of persistent shoulder pain with sodium hyaluronate: a randomized, controlled trial. A multicenter study. *J Bone Joint Surg Am.* 2008 May;90(5):970-9.
- (14) Merolla G, Sperling JW, Paladini P, Porcellini G. Efficacy of Hylan G-F 20 versus 6-methylprednisolone acetate in painful shoulder osteoarthritis: a retrospective controlled trial. *Musculoskelet Surg.* 2011 Dec;95(3):215-24
- (15) Gross C, Dhawan A, Harwood D, Gochanour E, Romeo A. Glenohumeral joint injections: a review. *Sports Health.* 2013 Mar;5(2):153-9.
- (16) Xie X, Zhang C, Tuan RS. Biology of platelet-rich plasma and its clinical application in cartilage repair. *Arthritis Research & Therapy* 2014;16(1):204.
- (17) Zhu Y, Yuan M, Meng HY, Wang AY, Guo QY, Wang Y, Peng J. Basic science and clinical application of platelet-rich plasma for cartilage defects and osteoarthritis: a review. *Osteoarthritis Cartilage.* 2013 Nov;21(11):1627-37.
- (18) Lathia AT, Jung SM, Chen LX. Efficacy of acupuncture as a treatment for chronic shoulder pain. *Journal of Alternative & Complementary Medicine.* 2009;15(6):613-8.
- (19) Jang JS, Choi HJ, Kang SH, Yang JS, Lee JJ, Hwang SM. Effect of pulsed radiofrequency neuromodulation on clinical improvements in the patients of chronic intractable shoulder pain. *J Korean Neurosurg Soc.* 2013
- (20) Namdari S, Skelley N, Keener JD, Galatz LM, Yamaguchi K. What is the role of arthroscopic debridement for glenohumeral arthritis? A critical examination of the literature. *Arthroscopy.* 2013 Aug;29(8):1392-8.
- (21) Millett PJ, Horan MP, Pennock AT, Rios D. Comprehensive Arthroscopic Management (CAM) procedure: clinical results of a joint-preserving arthroscopic treatment for young, active patients with advanced shoulder osteoarthritis. *Arthroscopy.* 2013 Mar;29(3):440-8.
- (22) Izquierdo R, Voloshin I, Edwards S, et al. Treatment of glenohumeral osteoarthritis. *J Am Acad Orthop Surg.* 2010;18(6):375-382
- (23) Lo IKY, Litchfield RB, Griffin S, Faber K, Patterson SD, Kirkley A. Quality-of-life outcome following hemiarthroplasty or total shoulder arthroplasty in patients with osteoarthritis. A prospective, randomized trial. *J Bone Joint Surg Am.* 2005;87:2178-2185.
- (24) Norris TR, Iannotti JP. Functional outcome after shoulder arthroplasty

for primary osteoarthritis: A multicenter study. *J Shoulder Elb Surg.* 2002;11(Figure 1):130-135.

- (25) Boorman RS, Kopjar B, Fehring E, Churchill RS. The effect of total shoulder arthroplasty on self-assessed health status is comparable to that of total hip arthroplasty. *J Shoulder Elb Surg.* 1997:158-163
- (26) Namdari S, Alosch H, Baldwin K et al. Biological glenoid resurfacing for glenohumeral osteoarthritis: a systematic review. *Journal of Shoulder & Elbow Surgery.* 2011;20(7):1184-90
- (27) Puskas GJ, Meyer DC, Lebschi JA, Gerber C. Unacceptable failure of hemiarthroplasty combined with biological glenoid resurfacing in the treatment of glenohumeral arthritis in the young. *J Shoulder Elbow Surg.* 2015 Dec;24(12):1900-7.
- (28) Clinical outcomes of hemiarthroplasty and biological resurfacing in patients aged younger than 50 years. Hammond LC, Lin EC, Harwood DP, Juhan TW, Gochanour E, Klosterman EL, Cole BJ, Nicholson GP, Verma NN, Romeo AA. *J Shoulder Elbow Surg.* 2013 Oct;22(10):1345-51.
- (29) Olivier A. van der Meijden, Trevor R. Gaskill, and Peter J. Millett, "Glenohumeral Joint Preservation: A Review of Management Options for Young, Active Patients with Osteoarthritis," *Advances in Orthopedics*, vol. 2012, Article ID 160923, 9 pages, 2012
- (30) Sanjeev Bhatia, Andrew Hsu, Emery C. Lin, et al., "Surgical Treatment Options for the Young and Active Middle-Aged Patient with Glenohumeral Arthritis," *Advances in Orthopedics*, vol. 2012, Article ID 846843, 8 pages, 2012
- (31) Saltzman MD1, Chamberlain AM, Mercer DM, Warme WJ, Bertelsen AL, Matsen FA 3rd. Shoulder hemiarthroplasty with concentric glenoid reaming in patients 55 years old or less. *J Shoulder Elbow Surg.* 2011 Jun;20(4):609-15.
- (32) Clinton J1, Franta AK, Lenters TR, Mounce D, Matsen FA 3rd. Nonprosthetic glenoid arthroplasty with humeral hemiarthroplasty and total shoulder arthroplasty yield similar self-assessed outcomes in the management of comparable patients with glenohumeral arthritis. *J Shoulder Elbow Surg.* 2007 Sep-Oct;16(5):534-8.
- (33) Pritchett JW. Long-term results and patient satisfaction after shoulder resurfacing. *J Shoulder Elbow Surgery* 2011 Jul;20(5):771-7.
- (34) Levy O, Copeland SA. Cementless surface replacement arthroplasty (Copeland CSRA) for osteoarthritis of the shoulder. *J Shoulder Elbow Surg.* 2004 May/June; 13(3):266-71

- (35) Alizadehkhayat OI, Kyriakos A, Singer MS, Frostick SP. Outcome of Copeland shoulder resurfacing arthroplasty with a 4-year mean follow-up. *J Shoulder Elbow Surg.* 2013 Oct;22(10):1352-8.
- (36) Graves S. National Joint Replacement Registry - Shoulder arthroplasty annual report 2015 [Internet]. Australian Orthopaedic Association; Available from: <https://aoanjrr.dmac.adelaide.edu.au/documents/10180/217645/Shoulder%20Arthroplasty>
- (37) Rasmussen JV, Polk A, Sorensen AK, Olsen BS, Brorson S. Outcome, revision rate and indication for revision following resurfacing hemiarthroplasty for osteoarthritis of the shoulder 837 operations reported to the Danish Shoulder Arthroplasty Registry. *Bone & Joint Journal.* 2014;96(4):519-25.
- (38) Al-Hadithy NI, Domos P, Sewell MD, Naleem A, Papanna MC, Pandit R. Cementless surface replacement arthroplasty of the shoulder for osteoarthritis: results of fifty Mark III Copeland prosthesis from an independent center with four-year mean follow-up. *Shoulder Elbow Surg.* 2012 Dec;21(12):1776-81
- (39) Huguet D, DeClercq G, Rio B, Teissier J, Zipoli B. Results of a new stemless shoulder prosthesis: Radiologic proof of maintained fixation and stability after a minimum of three years' follow-up. *J Shoulder Elbow Surg.* 2010;19:847-52
- (40) Bell SN and Coghlan JA Short stem shoulder replacement.. *Int J Shoulder Surg.* 2014 Jul-Sep; 8(3): 72-75.
- (41) Berth A, Pap G. Stemless shoulder prosthesis versus conventional anatomic shoulder prosthesis in patients with osteoarthritis: A comparison of the functional outcome after a minimum of two years follow-up. *J Orthop Traumatol.* 2013;14:31-7.
- (42) Habermeyer P, Lichtenberg S, Tauber M, Magosh M. Midterm results of stemless shoulder arthroplasty: a prospective study. *Journal of Shoulder & Elbow Surgery.* 20015;24:1463- 72.
- (43) Fevang B-TS, Lygre SHL, Bertelsen G, Skredderstuen A, Havelin LI, Furnes O. Pain and function in eight hundred and fifty nine patients comparing shoulder hemiprostheses, resurfacing prostheses, reversed total and conventional total prostheses. *Int Orthop.* 2013 Jan;37(1):59-66.
- (44) Rasmussen JV, Polk A, Brorson S, Sørensen AK, and Olsen BS. Patient-reported outcome and risk of revision after shoulder replacement for

osteoarthritis 1,209 cases from the Danish Shoulder Arthroplasty Registry, 2006–2010. *Acta Orthopaedica* 2014; 85 (2): 117–122

- (45) Edwards TB, Kadakia NR, Boulahia A et al. A comparison of hemiarthroplasty and total shoulder arthroplasty in the treatment of primary glenohumeral osteoarthritis: results of a multicenter study. *Journal of Shoulder & Elbow Surgery*. 2003;12(3):207-13.
- (46) Radnay CS, Setter KJ, Chambers L et al. Total shoulder replacement compared with humeral head replacement for the treatment of primary glenohumeral osteoarthritis: a systematic review. *Journal of Shoulder & Elbow Surgery*. 2007;16(4):396-402.
- (47) Gartsman GM, Roddey TS, Hammerman SM. Shoulder arthroplasty with or without resurfacing of the glenoid in patients who have osteoarthritis. *J Bone Joint Surg Am*. 2000 Jan;82(1):26–34.
- (48) Bryant D, Litchfield R, Sandow M et al. A comparison of pain, strength, range of motion, and functional outcomes after hemiarthroplasty and total shoulder arthroplasty in patients with osteoarthritis of the shoulder. A systematic review and meta-analysis. *Journal of Bone & Joint Surgery - American Volume*. 2005;87(9):1947-56.
- (49) Gartsman GM, Roddey TS, Hammerman SM. Shoulder arthroplasty with or without resurfacing of the glenoid in patients who have osteoarthritis. *J Bone Joint Surg Am*. 2000 Jan;82(1):26–34.
- (50) Singh JA, Sperling J, Buchbinder R et al. Surgery for shoulder osteoarthritis. *Cochrane Database of Systematic Reviews*. 2010;(10)
- (51) Litchfield RB, McKee MD, Balyk R et al. Cemented versus uncemented fixation of humeral components in total shoulder arthroplasty for osteoarthritis of the shoulder: a prospective, randomized, double-blind clinical trial-A JOINTs Canada Project. *Journal of Shoulder & Elbow Surgery*. 2011;20(4):529-36.
- (52) Singh J, Sperling J, Cofield R. Revision surgery following total shoulder arthroplasty: analysis of 2588 shoulders over three decades (1976 to 2008). *J Bone Joint Surg Br*. 2011;93-B(11):1513-7.